

**Research Article**

## **Sciatic Nerve : Site of Division into Tibial and Common Peroneal Nerves and Clinical Implications.**

**Pasuk Mahakkanukrauh\*, Vichit Somsarp\*, Tejatat Tejasen\***

### **Abstract**

**Background :** A description of the division site of the sciatic nerve into tibial and common peroneal nerves in Thai subjects has never been available. A precise knowledge is desirable for an execution of surgically orientated intervention. Various textbooks and reports have been diversified mostly without exact percentage for each division site.

**Method :** To establish the pattern of division, we dissected sixty-five cadavers (130 specimens) of both sexes, aging between 14 and 92. Measurements of the nerves were made to note the precise point of division.

**Results :** The division pattern was classified into four types. From a total of 130 specimens, 40.7% (53 specimens) was at the level of the femoral condyle (Type I), 25.3% (33 specimens) was at the gluteal region (Type II), 24.6% (32 specimens) was at about the popliteal space (Type III), and 8.4% (11 specimens) was at the mid-thigh level (Type IV). Only one specimen presented at the lower third of the thigh. Intra-cadaveric variation was quite commonly noted. However, Type I division pattern has not been described before.

**Conclusions :** Sciatic nerve divisions in Thais were briefly stated that 65% at the knee level, 25% at the gluteal region and the rest at the thigh. These findings would have strong clinical implications in surgical, anaesthetic and rehabilitative interventions.

**Key words :** Sciatic nerve division, tibial nerve, common peroneal nerve

---

\* Department of Anatomy, Faculty of Medicine, Chiang Mai University.

## บทคัดย่อ : เส้นประสาท Sciatic : จุดแยกตัวเป็นเส้นประสาท Tibial กับเส้นประสาท Common Peroneal และความสำคัญทางคลินิก

ผาสุก มหรรณานุเคราะห์\* วิจิต สมทรัพย์\* เตชะทัต เตชะเสน\*

เนื่องจากมีรายงานพบการแบ่งแยกแขนงของเส้นประสาท Sciatic เป็นเส้นประสาท Tibial และเส้นประสาท Common Peroneal ที่แตกต่างกันไปตามตำราต่างๆ ไปอยู่เนืองๆ ประกอบกับมีอาจค้นพบการศึกษาดังกล่าวในตำราภาษาไทยใดๆ ก็ตรงกับความรู้ดังกล่าวมีความสำคัญต่อการรักษาทางศัลยกรรม คณะผู้รายงานจึงได้ศึกษาการแบ่งแยกดังกล่าวในศพคนไทย 65 ราย (เส้นประสาท 130 เส้น) วัย 14-92 ปี พบการแยกตัวหลักๆ เป็นสี่แบบ ดังนี้คือ ร้อยละ 40.7 (เส้นประสาท 53 เส้น) แบ่งแยกที่ปลายกระดูกต้นขา (แบบที่ 1), ร้อยละ 25.3 (เส้นประสาท 33 เส้น) แบ่งแยกที่บริเวณสะโพก (แบบที่ 2), ร้อยละ 24.6 (เส้นประสาท 32 เส้น) แบ่งแยกที่บริเวณเข่า (แบบที่ 3) และ ร้อยละ 8.4 (เส้นประสาท 11 เส้น) แบ่งแยกที่กลางต้นขา (แบบที่ 4) และมีเพียงเส้นเดียวแบ่งแยกที่เศษหนึ่งส่วนสามล่างของต้นขา ทั้งนี้มักมีความผิดปกติแตกต่างในศพเดียวกัน ด้วย สำหรับการแบ่งแยกแขนงของเส้นประสาท Sciatic แบบที่หนึ่งไม่เคยมีรายงานมาก่อนหน้านี้ กล่าวโดยสรุป เส้นประสาท Sciatic ในคนไทยแบ่งแยกเป็นแขนง Tibial และแขนง Common Peroneal ที่เข่าร้อยละ 65 ที่สะโพกร้อยละ 25 และที่เหนือแบ่งในต้นขา ผลการศึกษานี้จะน่าจะมีประโยชน์ทางคลินิกในการรักษาทั้งทางศัลยกรรม วิสัญญีวิทยา และเวชศาสตร์ฟื้นฟู

คำรหัส : Sciatic nerve division, tibial nerve, common peroneal nerve

---

\* ภาควิชากายวิภาคศาสตร์ คณะแพทยศาสตร์ มหาวิทยาลัยเชียงใหม่

## Introduction

Injury to the sciatic nerve causes a devastating catastrophe, entailing muscular weakness, joint contracture, limb deformities, trophic ulcerations and abnormal gait. Knowledge of exact anatomy is thus a key for successful surgical, anaesthetic and rehabilitative interventions.

The sciatic nerve is the largest branch contributed by the lumbosacral plexus. It consists of two nerves, the tibial and the common peroneal, bound together in the same sheath to form the largest nerve in the body with a width of about two centimeters, leaving the pelvis through the greater sciatic foramen, underneath the belly of the piriformis muscle, covered by the gluteus maximus muscle before branches into those two major components. The precise point of branching of the nerve has been described differently in various textbooks as in the pelvis<sup>1,3</sup>, gluteal region<sup>1,3-6</sup>, upper thigh<sup>1,3-6</sup>, mid-thigh<sup>2,7</sup>, distal thigh or lower third of thigh<sup>1-3, 8, 8-11</sup> and upper part or apex of popliteal fossa<sup>5,12-14</sup>. However, the specimens donated for teaching purpose at Department of Anatomy, Faculty of Medicine, Chiang Mai University were found to have more different patterns of division. There was no previous study of the sciatic nerve branching reported in Thailand. We thus endeavored to study the location of the main branching of the sciatic nerve in Thai subjects.

## Materials and Methods

The study was carried out on sixty-five cadavers of both sexes (thirty-nine males, twenty-six females), aged between fourteen and ninety-two years. All were Thai who had donated their bodies for teaching purpose at the Department of Anatomy, Faculty of Medicine, Chiang Mai University.

Dissection was carried out by removing the skin down to muscular level from the gluteal region to the back of the knee. The gluteus maximus muscle was completely detached from its medial attachment started from the lower border then reflected the muscle laterally. The gluteus medius muscle would now come into view. It was further detached from its insertion and lifted up to expose the gluteus minimus and the piriformis. The sciatic nerve could now be located at the distal border of the piriformis muscle. The nerve could be followed to the point of its branching into the two major components of tibial and common peroneal nerves. Lengths from the point of its emergence underneath the belly of the piriformis to the point of its branching and also to the lateral condyle of the femur were then measured.

## Results

One hundred and thirty specimens from sixty-five cadavers were studied. All sciatic nerves passed beneath the piriformis muscle. Of these, the point of branching into the two major components of tibial and common

peroneal nerves could be grouped into four types, as follow :

Type I : At the level of the femoral condyle (Figure 1, 2). Thirty-four cadavers (52.3%) with twenty-one males (32.3%) and thirteen females

(20.0%) made a total of fifty-three specimens (40.7%) in this group. The detail was shown in Table 1. No report or description of this pattern was described before.



Figure 1 : The division of the sciatic nerve at the level of the femoral condyle (arrow). K = Knee

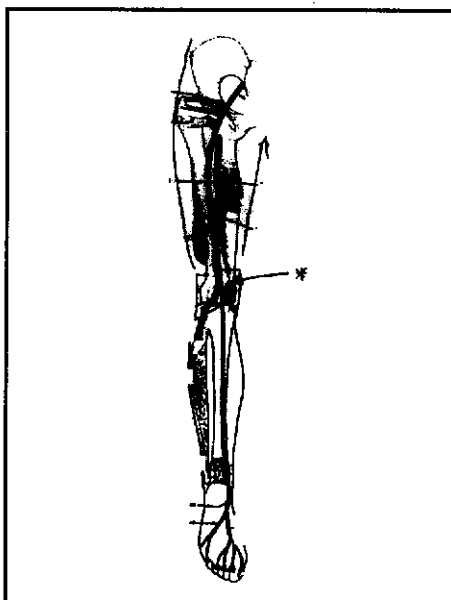


Figure 2 : Site of division : At the level of the femoral condyle (\*).

Table 1 : The number, side and sex of cadavers and specimens showing the division site at the femoral condylar region.

Type	Cadavers			Specimen
	Male	Female	Total	
Symmetrical bilateral	15	4	19	38
Left side only	2	5	7	7
Right side only	4	4	8	8
Total (%)	21 (32.3)	13 (20)	34 (52.3)	53 (40.7)

Type II : At The gluteal region (Figure 3, 4). This group comprised of twenty-one cadavers, ten males (15.0%) and eleven

females (17.0%), with thirty-three specimens (25.3%) as shown in Table 2.

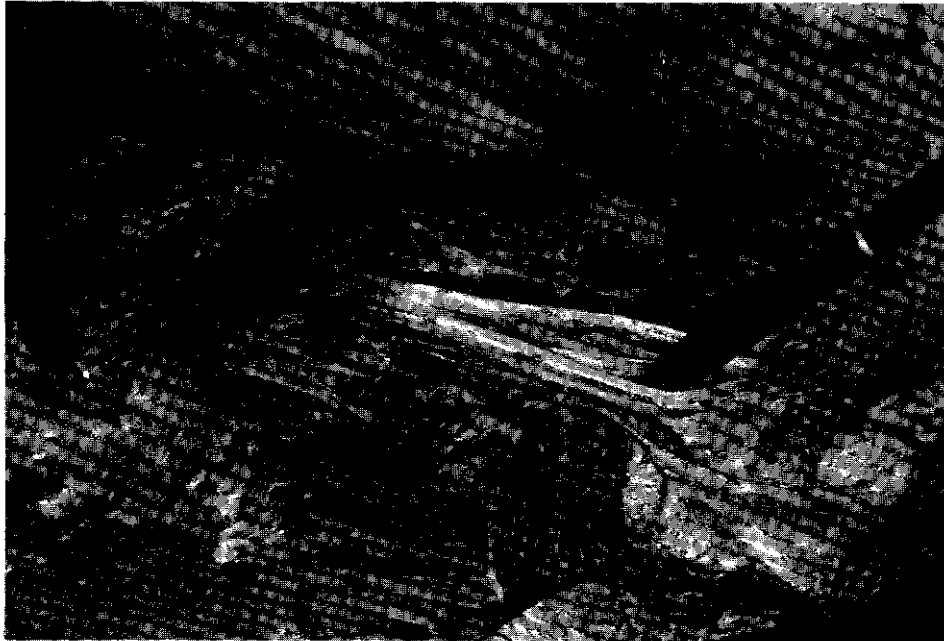


Figure 3 : The division of the sciatic nerve at the gluteal region (arrow). A = Piriformis muscle

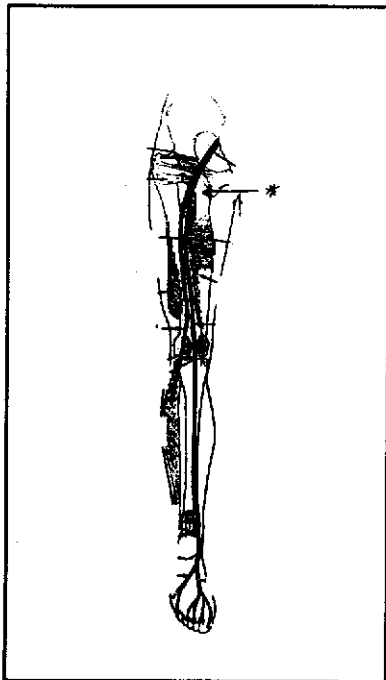


Figure 4 : Site of division : At the gluteal region (\*)

Table 2 : The number, side and sex of cadavers and specimens showing the division site at the gluteal region.

Type	Cadavers			Specimen
	Male	Female	Total	
Symmetrical bilateral	5	7	12	24
Left side only	4	4	8	8
Right side only	1	-	1	1
Total (%)	10 (15)	11 (17)	21 (32.5)	33 (25.3)

Type III : About the popliteal space : Not exceed to eight centimeters above the femoral condyle (Figure 5, 6). Twenty-two cadavers (33.8%) with twelve males (18%) and ten

females (15%) made a total of thirty-two specimens (24.6%) in this group. The detail was shown in Table 3.




Figure 5 : The division of the sciatic nerve at the superior end of the popliteal fossa (arrow).

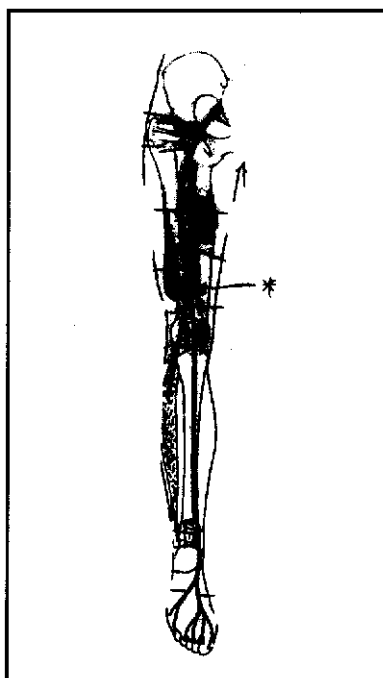


Figure 6 : Site of division : About the popliteal space (\*)

Table 3 : The number, side and sex of cadavers and specimens showing the division at about the popliteal space (not exceed to 8 cm. above the femoral condyle).

Type	Cadavers			Specimen
	Male	Female	Total	
Symmetrical bilateral	6	4	10	20
Left side only	3	0	3	3
Right side only	3	6	9	9
Total (%)	12 (18)	10 (15)	22 (33.8)	32 (24.6)

Type IV : At mid-thigh level : between eleven to twenty-five centimeters from piriformis (Figure 7, 8). The 5.5 cadavers (four males and two females) made a total of eleven specimens (8.4%) in this group. The detail was shown in Table 4.

Only one left thigh specimen of a seventy-seven years old male, the nerve divided at the lower third level of the thigh,

where as the nerve deviation on his right thigh was observed at the mid-thigh level.

Further perusal revealed that six cadavers (3 males and 3 females) possessed the division of nerve in the gluteal region on one side and at the femoral condyle on the other side. All but one had the division on left buttock and right knee, *vice versa* were found in the others (Figure 9).

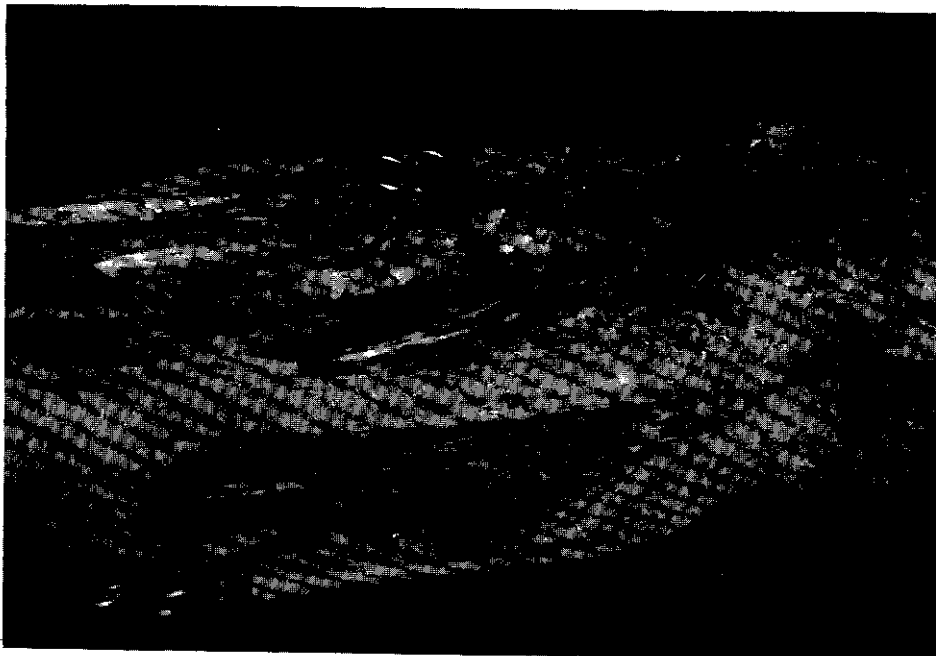


Figure 7 : The division of the sciatic nerve at the mid-thigh level (over scissor). G = Gluteus maximus

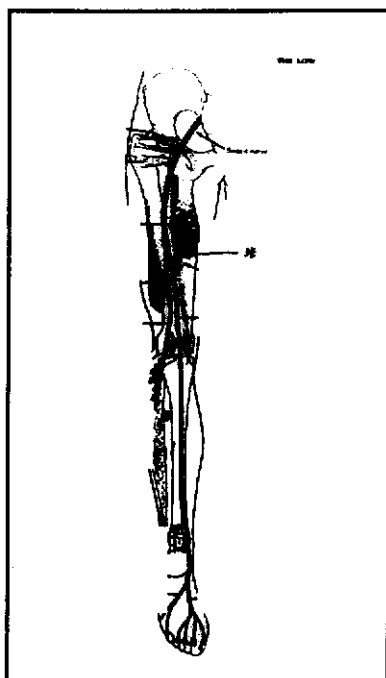


Figure 8 : Site of division : At mid-thigh level (\*)

Table 4 : The number, side and sex of cadavers and specimens showing the division at the mid-thigh level (between 11–25 cm. from the piriformis).

Type	Cadavers			Specimen
	Male	Female	Total	
Bilateral	3	2	5	10
Unilateral	1*	0	1	1
Total (%)	4* (6)	2 (3)	6* (9.2)	11 (8.4)

\* Actually 5 cadavers plus one specimen.



Figure 9 : Intracadaveric variations. One sciatic nerve divided in the gluteal region (over scissor), while the opposite side divided at the femoral condyle (over a scalpel).



## Discussion

The relationship of the sciatic nerve to piriformis muscle as quoted from a standard textbook is as follow: Of 640 limbs studied, 87.3% had both tibial and common peroneal divisions passing below piriformis muscle, 12.2% had the peroneal division passing through piriformis muscle, 0.5 % had the peroneal division passing above. All sciatic nerves in our study passed below the piriformis muscle, although the number of our specimens (130) were much less.

Gosling *et al*<sup>1</sup>, Moore<sup>2</sup> and Snell<sup>3</sup> described the division of the sciatic nerve in the pelvis although no percentage of the division was given. However, the division at this level was not found in our study.

Chiba<sup>16</sup> reported a study of 514 sciatic nerves which 179 (30.5%) divided into tibial and common peroneal nerves about the piriformis muscle, *i.e.* in the gluteal region. However, this division site was found in 25.3% of our specimens. Craggs<sup>4</sup>, Gosling *et al*<sup>1</sup>, Last<sup>5</sup>, Moore & Agur<sup>6</sup> and Snell<sup>3</sup> also described the division of sciatic nerve in this region but no exact percentage was given.

Moore<sup>2</sup> and Snell<sup>7</sup> described the division of the sciatic nerve in mid-thigh whereas only 8.4% of our specimens was found the branching at this level.

Many authors<sup>5,12-14</sup> described the division of the sciatic nerve into the tibial and common peroneal nerves at the superior end of the popliteal fossa, and many others<sup>1-3, 6, 8-11</sup>

described the division site at the lower third of the thigh. Although they were at different levels, they were in quite a close proximity. Therefore, these characteristics could be grouped to our Type III branching. Twenty-two cadavers could then be allocated to this group with 32 specimens (24.6%).

However, the sciatic nerve from one of our specimens did divide at the lower third of the thigh while the opposite side divided in the mid-thigh.

From the results of our study, Type I and Type III in combination made the largest group (of close proximity) of division about the knee in fifty-six cadavers or eighty-five specimens (65.4%). Thus, more than half of the sciatic nerves in Thai individuals divided into tibial and common peroneal nerves at the knee region. Of these thirty-three were males and twenty-three were females. For those which divided in the mid-thigh accounted for only 8.4% in our series with no significant difference between males and females.

The most interesting finding in this study was that 40.7% of our specimens the division site took place at the level of the femoral condyle. This finding has never been described before.

Equipped with these facts, a surgeon (a general surgeon, a neurosurgeon or an orthopaedist) would be better prepared for carrying out a successful surgical intervention<sup>17</sup>. In another aspect, a rehabilitation physician would be better facilitated in carrying

out nerve conduction study<sup>18-20</sup>, nerve stimulation<sup>21</sup> or electrical stimulation to keep the bulk of the muscle in rehabilitation of patients<sup>18-20</sup>. An anesthesiologist would likewise be better armed to carry out nerve blocking on the sciatic, common peroneal, or tibial nerves<sup>22-23</sup>.

Although this study was encountered with quite a lot of variations to what had been described previously. We did think that it would contribute to enhance the successful execution of these interventions in general or at least in the Thai population in the North.

## Conclusion

Sciatic nerve found in this study divided into two major components of tibial and common peroneal nerves at 4 locations: the gluteal region (25.3%), the mid-thigh region (8.4%), the popliteal space (24.6%) and the femoral condylar region (40.7%). Thus the division around the knee accounted for more than half. Division at the femoral condyle region was first described here. Intracardaveric variations were quite commonly noted.

## Acknowledgement

This study was supported by a grant from the research committee of the Faculty of Medicine, Chiang Mai University, for which we are thankful.

The authors would also like to thank Associate Professor Chanintr Mahakkanukrauh for his helpful assistance in the preparation of the manuscript.

No benefits in any forms have been received or will be received from a commercial party related directly or indirectly to the subject of this article.

## References

1. Whitmore I, Willan PLT. Lower Limb. In : Gosling JA, (eds). Human Anatomy Color Atlas and Text. 3rd ed, London : Mosby-Wolfe, 1996.
2. Moore KL. Lower Extremity. In : Moor KL (ed). Clinically Oriented Anatomy. 3rd ed, Baltimore : Williams & Wilkins, 1992.
3. Snell RS. Clinical Anatomy for Medical Students. 4th ed, London : Brown and Co, 1986.
4. Craggs ECBH. Anatomy as a Basis for Clinical Medicine. London : Williams & Wilkins, 1995.
5. Last RJ. Anatomy Regional and Applied. 6th ed, Edinburgh : Churchill-Livingstone, 1978.
6. Moore KL, Agur AMG. Lower Limb. In : Moore KL (ed). Essential Clinical Anatomy. Maryland : Williams & Wilkins, 1996: 358.
7. Snell RS. Atlas of Clinical Anatomy. Boston : Little, Brown and Co, 1992.
8. Leonard RJ. Human Gross Anatomy. New York : Oxford University Press, 1995.
9. Palastanga N, Field D, Soames R. Anatomy and Human Movement. Oxford : Butterworth-Heinemann, 1989.
10. Slaby FJ, McCune SK, Summers RW. Gross Anatomy in the Practice of

- Medicine. Philadelphia : Lea & Febiger, 1994.
11. Woodburne RT, Burkel WE. Essentials of Human Anatomy. 5th ed. New York : Oxford University Press, 1973.
12. McMinn RMH, Rosse PG, Hutching RT, Logan BM. Functional Clinical Anatomy, New York : Mosby, 1995.
13. Moffat DB. Lecture Notes on Anatomy. 2nd ed. London : Blackwell Scientific Publ, 1987.
14. Pansky B. Review of Gross Anatomy. 5th ed. New York : McGraw-Hill, 1996.
15. Anderson JA. Grant's Atlas of Anatomy. 7th ed. Maryland: Williams & Wilkins, 1978.
16. Chiba S. Multiple positional relationships of nerves arising from the sacral plexus to the piriformis muscle in humans. Kaibogaku-Zasshi 1992; 67: 691-724.
17. Wright PE. Campbell's Operative Orthopaedics. 7th ed. St. Louis, Missouri : The CV Mosby, 1987.
18. Inaba A, Yokota T, Komori T, Hirose K. Proximal and segmental motor nerve conduction in the sciatic nerve produced by percutaneous high voltage electrical stimulation. Electroencephalogr Clin Neurophysiol 1996; 101: 100-4.
19. Kimura J. Electrodiagnosis in Diseases of Nerve and Muscle : Principle and Practice. Philadelphia : FA Davis, 1983.
20. Yap CB, Hirota T. Sciatic nerve conduction velocity study. J Neurol Neurosurg Psychiatry 1967; 30: 233-9.
21. Nashold BS Jr, Goldner JL, Mullen JB, Bright GS. Long-term pain control by direct peripheral nerve stimulation. J Bone Joint Surg 1982; 64: 1-10.
22. Atkinson RS, Rushman GB, Lee JA. A Synopsis of Anaesthesia. 10th ed. Bristol: IOP Publ Ltd, 1987.
23. Zetlaoui PJ. Sciatic nerve block. Can Anesthesiol 1996; 44: 119-26.