Journal of Associated Medical Sciences 2027; 60(1): 319-327

JAMS
Journal of Associated Medical Sciences

Scopus Indexed & Thai-Journal Citation Index Centre (TCI)

Journal of Associated Medical Sciences

Journal homepage: https://www.tci-thaijo.org/index.php/bulletinAMS/index



The feasibility of a positive expiratory pressure device for lung expansion and shoulder range of motion in thoracotomy patients

Saikaew Chuachan[1*], Pattamar Phadermpol[2], Supalak Abuwa[3], Jatuporn Jaturawanit[4], Porraporn Sriwannawit[5], Voravit Chittithavorn[6]

[1]*Department of Physical Therapy, Faculty of Medicine, Prince of Songkla University, Songkhla, Thailand.*
[2]*Physicaltherapy Unit, Phangnga Hospital, Phangnga, Thailand.*
[3]*Physicaltherapy Unit, Krongpinang Hospital, Yala, Thailand.*
[4]*Physical Therapy Unit, Songklanagarind Hospital, Faculty of Medicine, Prince of Songkla University, Songkla, Thailand.*
[5]*Department of Physical Therapy, Faculty of Allied Health Sciences, Rattana Bundit University, Bangkok, Thailand.*
[6]*Department of Surgery, Faculty of Medicine, Prince of Songkla University, Songkla, Thailand.*

ARTICLE INFO

ORCID of all authors
Saikaew Chuachan: https://orcid.org/0000-0002-1533-3399
Pattamar Phadermpol: None
Supalak Abuwa: None
Jatuporn Jaturawanit: None
Porraporn Sriwannawit: http://orcid.org/0000-0003-4539-7972
Voravit Chittithavorn: None

Correspondence
Saikaew Chuachan
Department of Physical Therapy, Faculty of Medicine, Prince of Songkla University, Songkhla, Thailand.
Email: saikaew.ch@psu.ac.th

Article history
Received 27 April 2025
Accepted as revised 17 November 2026
Available online 25 November 2026

Keywords
thoracotomy, lung expansion, shoulder range of motion, positive expiratory pressure breathing

doi: 10.66285/JAMS.2027.029
E-ISSN: 2539-6056

ABSTRACT

Background: Thoracic surgery leads to respiratory muscle injury and a decrease in lung expansion and shoulder joint movement. Positive expiratory pressure (PEP) breathing with conventional chest physical therapy techniques may improve lung volume.

Objectives: To evaluate the effects of PEP breathing on lung expansion and shoulder range of motion after training in thoracotomy patients.

Materials and methods: Eighteen thoracotomy patients (ages between 31 and 83 years) who met inclusion criteria received PEP breathing at 15 cmH_2O loading, 15 breaths/set, 12 sets/day with conventional chest physical therapy. Comparisons of slow vital capacity (SVC), chest wall expansion, and shoulder ranges of motion at pre-operative, post-operative, and before discharge from the hospital were analyzed using repeated-measures ANOVA and Tukey HSD post hoc tests.

Results: The results showed significant improvement in SVC ($p<0.001$) and chest wall expansion ($p<0.01$). Shoulder range of motion showed a significant increase in flexion ($p<0.001$) and abduction ($p<0.001$) between pre-operative, post-operative, and before discharge from the hospital.

Conclusion: PEP breathing combined with conventional chest physiotherapy treatment could improve lung expansion and shoulder motion in thoracotomy patients. Randomized controlled trials should be conducted in future studies.

Introduction

Patients who have undergone thoracotomy directly impact the respiratory system, leading to impaired respiratory muscle function and decreased chest expansion.[1] Inflammation around the surgical site contributes to pain and limits movement of the chest, shoulders, and trunk, reducing patients' ability to perform daily activities independently.[2,3] In addition, functional residual capacity (FRC) and vital capacity (VC) tend to decline with age,[4] but thoracotomy surgery is a major contributing factor to further reductions in these lung volumes by as much as 40-46% and 70%, respectively.[5,6] Furthermore, this also impairs pulmonary ventilation at the base of the lungs and increases the risk of subsequent atelectasis.[7,8] Positive expiratory pressure (PEP) breathing exercises are commonly used after thoracic and abdominal surgeries to enhance lung expansion and reduce pulmonary complications. These exercises involve exhalation against resistance, typically ranging from 5-20 cmH_2O, delivered via devices such as the PEP mask and blow bottle PEP.[6,9-15] A positive expiratory pressure (PEP) device is commonly used in patients undergoing thoracoabdominal surgery, with recommended training pressures ranging from 10-20 cmH_2O.[6,12,13] Previous studies have found that using a 15 cmH_2O setting with the blow bottle PEP device is more effective than other devices.[13]

Therefore, the researchers decided to use this level of resistance in this study. Additionally, prior research has shown that PEP can increase respiratory effort,[13] enhance respiratory muscle performance,[9] and improve oxygenation when combined with deep breathing exercises.[6] In post-thoracotomy patients, additional benefits include increased lung volumes, better secretion clearance, and improved chest wall expansion.[12] These effects help reopen collapsed alveoli, improve gas exchange, and reduce postoperative fatigue, which may contribute to shorter hospital stays and lower healthcare costs. PEP devices are also considered safe and easy to use.

Shoulder mobility is another concern after thoracic surgery, as incisional pain and stiffness can limit shoulder abduction and flexion, particularly following procedures such as median sternotomy.[16] These limitations can further interfere with daily functioning. However, despite the demonstrated benefits of PEP in improving lung function, its use in post-thoracotomy patients remains limited. Moreover, there is a lack of research on the comparative effectiveness of different PEP devices in promoting both respiratory and musculoskeletal recovery in this population.

BreatheMAX is a PEP device that provides expiratory resistance via a water-based mechanism, requiring patients to exhale through a tube submerged underwater. The bubbling feedback enhances user engagement and may improve adherence.[17,18] Although based on principles similar to blow bottle PEP, the effects of BreatheMAX on post-thoracotomy outcomes, particularly lung expansion and shoulder range of motion, have not been clearly established.

Therefore, this study aims to evaluate the effects of positive expiratory pressure (PEP) breathing using the BreatheMAX device on lung expansion and shoulder range of motion in patients after thoracotomy. This investigation addresses a gap in the literature and may provide evidence to support the use of PEP therapy as part of postoperative rehabilitation in this patient group.

Materials and methods

Study design

This quasi-experimental study was conducted among patients undergoing thoracotomy surgery at the cardiothoracic surgery unit. Ethical approval was

obtained from the institutional Ethics Committee (REC 56-005-11-82), and written informed consent was collected from all participants before enrollment.

Participants

Patients were eligible if they were aged 20 years or older, were cooperative with treatment, able to sit upright for at least 30 minutes postoperatively, had no neuromuscular complications (e.g., paralysis or phrenic nerve inflammation/injury confirmed by physician diagnosis), and demonstrated stable clinical symptoms. Unstable vital signs such as heart rate >120 beats/minute, respiratory rate >30 breaths/minute, blood oxygen saturation (SpO_2) <90%, systolic blood pressure >140 mmHg, and diastolic blood pressure <90 mmHg, loss of consciousness, and muscle weakness for an extended period, as well as those diagnosed with pneumothorax before or after surgery, were excluded from the study. A total of 18 participants were recruited through purposive sampling based on feasibility and availability. This sample size aligns with recommendations for pilot or exploratory quasi-experimental research.

PEP training program

Breathing exercises using the BreatheMAX device began on postoperative day 2 under supervision (Researcher A). The device setup included two bottles, providing an expiratory resistance of 15 cmH_2O. To generate a training resistance of 15 cmH_2O using the BreatheMAX device, each bottle was filled with water to a depth of 10 cm from the tip of the submerged exhalation tube. This depth creates a backpressure of 15 cmH_2O during exhalation, as the patient must overcome the hydrostatic pressure equivalent to the height of the water column in the bottle. Both bottles were filled to the same level to ensure consistent resistance throughout the training. Patients were instructed to perform 15 breaths per set, for a total of 12 sets per day, continuing this routine daily until hospital discharge. During the exercise, patients were guided to inhale deeply through the nose and exhale steadily through a mouthpiece into a water-filled tube, generating bubbles as visual feedback (Figure 1). This PEP training was integrated with standard thoracic physiotherapy, which included postural drainage, deep breathing exercises, surgical wound care, self-administered chest wall mobilization, and 30 minutes of walking each day.



Figure 1. Breathing exercise using BreatheMax.

Standard thoracic physiotherapy

In addition to the PEP program, all participants received standard thoracic physiotherapy following routine postoperative care protocols. This included postural drainage (5-10 minutes) to aid secretion clearance; diaphragmatic and segmental breathing exercises (6 breaths per set, 5-10 sets) to enhance alveolar expansion; and guidance on surgical wound care, including incision support techniques during movement or coughing. Patients were also instructed to perform gentle chest wall mobilization exercises (5-10 repetitions per day) to reduce stiffness and improve thoracic mobility. Supervised walking was encouraged for at least 30 minutes daily to promote circulation and functional recovery.

Outcome measurements

Baseline assessments included demographic data, medical history, height, weight, and surgical details. All participants received standard preoperative care from nursing staff and preoperative breathing training from physical therapists. Preoperative measurements were taken after five minutes of seated rest and included respiratory rate, SpO_2 using a Handheld pulse oximeter model M700, and heart rate and blood pressure using a Microlife BP 3BM1-3 blood pressure monitor, while patients were seated after a 5-min rest period before measurement. Pain levels were evaluated using the Visual Analog Scale (VAS) ranging from 0 to 10, with 0 indicating no pain and 10 indicating the highest level of pain. Fatigue levels were measured using the Modified Borg Scale, with scores ranging from 0 to 10, where 0 indicated no fatigue and 10 indicated the highest level of fatigue. These assessments were conducted both before and after each daily training session (Figure 2).

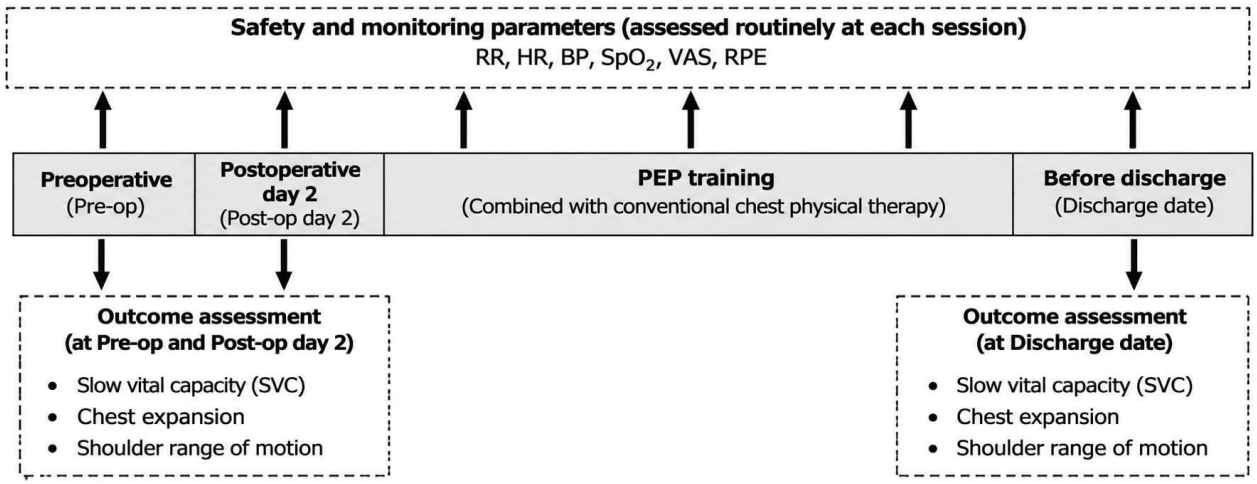

Figure 2. Study flow. SVC: slow vital capacity, RR: respiratory rate, HR: heart rate, BP: blood pressure, SpO_2: peripheral oxygen saturation, VAS: visual analog scale, RPE: rate perceived exertion, Pre-op: preoperative, Post-op day 2: postoperative day 2, PEP: positive expiratory pressure.

Chest wall expansion was measured at three anatomical levels: upper chest expansion (UCE) at the level of the 5th thoracic vertebra, just below the sternal angle and across the anterior axillary lines; middle chest expansion (MCE) at the level of the 4th rib along the mid-clavicular line; and lower chest expansion (LCE) at the level of the 10th rib, aligned anteriorly with the xiphoid process and posteriorly with the mid-scapular lines. Participants were instructed to fully exhale and then inhale maximally, with measurements taken in centimeters using a cloth tape. Three trials were performed, and the highest value was recorded. This method demonstrates strong intra-rater reliability (ICC: 0.85-0.98).

Shoulder range of motion (ROM) was assessed using a universal goniometer to measure active shoulder flexion and abduction. Participants raised their arms until discomfort or resistance occurred, and the angle was recorded. Goniometric measurements are highly reliable, with ICCs typically above 0.90.

Pulmonary function was evaluated via slow vital capacity (SVC) using a portable spirometer. Participants were instructed to breathe normally, inhale fully, then exhale slowly and completely into the spirometer. The best of three attempts was used for analysis. Spirometry is a validated and reliable tool, with reported ICCs exceeding 0.95 when standardized procedures are followed.

All outcomes were assessed at three time points: preoperatively, on postoperative day 2, and before hospital discharge (Figure 2). All outcome assessments, including chest wall expansion, slow vitalcapacity (SVC), and shoulder range of motion (ROM), were performed by a licensed physical therapist (Researcher B) with

over five years of clinical experience in cardiopulmonary rehabilitation. The examiner received specific training on standardized assessment procedures before the study to ensure consistency and accuracy. Intra-rater reliability was maintained by assigning the same examiner for all evaluations throughout the study period.

Statistical analysis

The mean values of SVC, shoulder range of motion in flexion and abduction, and chest wall expansion at the three levels (UCE, MCE, and LCE) were compared before surgery, on postoperative day 2, and before discharge from the hospital using repeated measures ANOVA and post hoc tests with Tukey's Honestly Significant Difference (HSD) test, with a significance level set at $p<0.05$.

Results

Eighteen patients underwent thoracotomy and met the study's criteria. Of these patients, 11 were male and 7 were female, with an average age of 55.33±13.72 years. Their average body mass index was 25.36 ±5.82 kg/m^2, and they stayed in the hospital for an average of 11.33±6.32 days. Most patients were diagnosed with lung cancer or had destroyed lungs and underwent thoracotomy, as shown in Table 1.

Table 1. General characteristics of the participants.

Patient	**Age** (years)	**Gender**	**BMI** (kg/m^2)	**Diagnosis**	**Method and type of surgery**	**LOS** (days)
1	36	Male	23.11	RUL aspergilloma	Rt. thoracotomy with cavernostomy with rib bone graft	19
2	31	Female	18.42	Spindle cell tumor LLL	Lt. thoracotomy with tumor removal	9
3	55	Male	23.31	RUL bullae	Rt. thoracotomy with bullectomy	20
4	39	Female	24.20	RUL nodule	Rt. thoracotomy with RUL lobectomy	7
5	44	Female	35.03	Bronchogenic cyst	Rt. thoracotomy with RUL lobectomy	14
6	51	Female	20.03	Bronchiectasis	Lt. thoracotomy with LUL lobectomy	7
7	54	Male	24.94	CA lung at RUL	Rt. thoracotomy with RUL lobectomy	9
8	51	Female	20.00	Pulmonary metastasis	Rt. thoracotomy with RUL lobectomy	9
9	83	Male	29.38	RUL bleb	Rt. thoracotomy with RUL lobectomy	7
10	72	Male	20.33	LUL CA lung	Lt. thoracotomy with LUL lobectomy	14
11	56	Female	37.10	Rt lung metastasis	Rt. thoracotomy to mastectomy	8
12	58	Male	22.78	Lt lung bullae	Lt. thoracotomy with LUL lobectomy	9
13	47	Male	27.61	adenocarcinoma CA lung at RML	Rt. Thoracotomy with RUL lobectomy	7
14	62	Male	18.44	RUL CA lung	Rt. thoracotomy with RUL lobectomy	31
15	50	Female	36.48	RUL mutates from rectum	Rt. thoracotomy with RUL lobectomy	8
16	69	Male	23.88	CA lung	Rt. thoracotomy with RLL lobectomy	9
17	74	Male	24.91	CA lung SqCCA	Lt. thoracotomy with LUL lobectomy	10
18	64	Male	26.57	CA metastasis	Lt. thoracotomy with LUL mastectomy	7

Note: BMI: body mass index, CA: cancer, SqCCA: squamous cell carcinoma, RUL: right middle lobe, LUL: left upper lobe, RML: right middle lobe, RLL: right lower lobe, LLL: left lower lobe, LOS: length of hospital stay, Rt: right, Lt: left.

All participants received standard postoperative analgesia as prescribed by their attending physicians. The primary regimen included intravenous paracetamol (1 gm every 6 hours) for the first 24-48 hours following surgery. As needed, tramadol (50-100 mg orally or intravenously every 6–8 hours) was administered based on individual pain levels. Medication administration was documented in the patients' medical records to ensure consistent pain management across participants. On postoperative days 1 to 5, average VAS scores ranged from 3 to 5, indicating moderate pain levels. By postoperative day 7, VAS scores typically declined to below 3, reflecting effective pain control and ongoing recovery.

At hospital discharge, participants showed significant improvements in respiratory function and physical measures when compared to preoperative assessments. Although SVC significantly declined by 982 mL on postoperative day 2 (p<0.001), it increased by 434 mL from day 2 to discharge (p<0.001). Compared to preoperative levels, the final SVC value at discharge remained lower by 548 mL (p<0.001), indicating partial recovery. Chest wall expansion at the upper, middle, and lower regions decreased by 0.97, 1.19, and 1.45 cm, respectively, on postoperative day 2 (p<0.01). However, these values significantly increased by 0.52, 0.72, and 0.81 cm, respectively, by the discharge date (p<0.01). Likewise, shoulder flexion and abduction decreased by 31 and 41 degrees, respectively, after surgery (p<0.001), but subsequently improved by 19 and 27 degrees following respiratory training with the resistance device, showing statistically significant differences (Table 2).

Table 2. Mean lung volume, chest expansion, and shoulder range of motion at the pre-operative, post-operative day 2, and discharge date.

Variables	Mean±SD			*p* value
	Pre-operative	Post-operative day 2	Discharge date	
Slow vital capacity (mL)	2150.00±357.95	1168.82±283.88*,‡	1602.94 ± 319.41*,†	< 0.001
Chest expansion				
upper part (cm)	3.64±1.03	2.67±0.84*	3.19±0.82	0.008
middle part (cm)	3.75±1.09	2.56±0.75*	3.28±1.05	0.002
lower part (cm)	3.89±0.93	2.44±0.97*	3.25±0.62†	<0.001
Shoulder range of motion				
flexion (degree)	178.33±5.14	147.00±24.37*	166.22±18.39†	<0.001
abduction (degree)	180.00±0.00	138.61±24.30*‡	166.06±17.46*†	<0.001

Note: *p<0.05 compared to preoperative, † p<0.05 compared to postoperative day 2, ‡ p<0.05 compared to discharge, p values in the last column reflect overall differences among the three time points, analyzed using repeated measures ANOVA with Bonferroni correction.

Discussion

This study indicates that combining positive expiratory breathing with chest physiotherapy can enhance lung expansion and shoulder mobility in post-thoracotomy patients. Physiotherapy interventions, including deep breathing exercises and chest mobilization, have been shown to improve both lung expansion and shoulder range of motion. Although incentive spirometry (IS) is commonly used in postoperative patients, studies report no significant differences in its effects on lung expansion compared to conventional chest physiotherapy treatment.[19,20]

In this study, a resistance level of 15 cmH_2O was chosen based on previous findings showing it to be more effective than lower pressures when using a blow bottle PEP device.[13] This moderate pressure is sufficient to activate the expiratory muscles without causing excessive fatigue or discomfort. PEP training increases intrathoracic pressure during exhalation, helping maintain airway patency, enhances secretion clearance, and improves alveolar ventilation.[6,9,12] The repetitive nature of PEP breathing also strengthens respiratory muscles and supports gradual recovery of chest wall mobility. Moreover, the combination of deep, controlled breathing with resistance likely engages accessory respiratory muscles and thoracic structures, contributing to better chest wall flexibility and shoulder mobility. These mechanisms may explain the observed improvements in shoulder range of motion, as increased thoracic excursion and reduced postoperative stiffness can alleviate movement restrictions, especially after thoracotomy.

Due to the limitations of BreathMax device used in this study, which can only provide 10-12 cmH_2O of resistance, we connected two bottles in series to achieve approximately 15 cmH_2O. Resistance was generated by adjusting the water level in each bottle. Despite these limitations, training with this device significantly increased lung expansion in patients following thoracic surgery.

Thoracotomy significantly reduces lung volume, increasing the risk of complications.[21] Functional residual capacity (FRC) and vital capacity (VC) have been shown to decrease by 40-45% and 70%, respectively.[5,6] In this study, patients' safety was a concern, especially in patients with complications like bullae; we used slow vital capacity (SVC) instead of VC. We found that SVC decreased by 54%, which was slightly less than previously reported.[6] Our study found that was 29% higher after 5-10 days of resistance training combined with conventional physiotherapy than on postoperative day 2. In contrast, Westerdahl *et al*. found no significant difference in lung volumes after four days of blow bottle PEP training at 10 cmH_2O compared to inspiratory resistance-PEP (IR-PEP) and deep breathing exercises.[13] Similarly, Urell *et al*. reported that PEP breathing set at 10-15 cmH_2O for three days improved oxygenation but did not enhance lung function.[6] Nonetheless, improvements may depend on factors such as collateral ventilation, which can influence bottle PEP effectiveness.[22,23] During expiration through resistive devices, patients typically hold their breath for 3-5 seconds, promoting expiratory muscle engagement.[23] Our findings support previous work by Westerdahl *et al*.[24] who demonstrated improved chest expansion at all levels after four days of PEP therapy post-cardiac surgery. These outcomes align with the physiological rationale behind PEP therapy: to recruit alveoli, reduce atelectasis, and enhance ventilation distribution. Although our study lacked a control group, improvements in lung volume and chest expansion at all levels suggest a positive response to the intervention. The combination of PEP and conventional physiotherapy likely contributed to alveolar recruitment and improved thoracic mobility. These findings support the potential role of PEP therapy in postoperative pulmonary rehabilitation. Future randomized studies with larger sample sizes are necessary to confirm these outcomes.

Pain plays a critical role in limiting postoperative recovery, particularly regarding chest expansion and breathing. All patients received standardized analgesic regimens, including intravenous paracetamol and tramadol as needed. The average VAS scores ranged from 4 to 6 during postoperative days 1-5 and dropped below 3 by day 7, suggesting that adequate pain control could help patients feel more comfortable after surgery.[25] In addition, a chest expansion therapy program can further enhance lung expansion.[26]

Shoulder range of motion was assessed on postoperative day 2 and again at discharge. During the early postoperative period, patients struggled with shoulder flexion and abduction due to factors such as pain, scar adhesion, and intercostal drains.[27] A previous study reported pain scores of 2-4 near the shoulder and chest wall during days 1-3 post-surgery.[28] Muscle tightness or injury to the shoulder flexors or abductors may also occur due to restricted movement. In this study, all patients underwent posterolateral thoracotomy, a surgical approach known to affect shoulder strength, pain levels, and functional capacity more than other methods.[16,29] Surgical procedures that involve muscle incision, rib retraction, or damage to thoracic structures may lead to post-operative pain, scar tissue formation, and muscle imbalance, which can limit shoulder mobility. In addition, adequate analgesia and early rehabilitation can support shoulder recovery, as reflected in our findings.[27,30]

Hospital stay length varied depending on the surgical technique, pathology site, complication severity, and individual recovery. Twelve patients were discharged within 10 days, especially those with fewer complications and younger age, indicating faster recovery. However, it should be noted that improvements in lung volume and mobility may not result solely from the intervention and could be influenced by other factors such as natural recovery or supportive care. Further studies are needed to explore these variables in more depth.

Limitations

The effectiveness of respiratory training with PEP devices in patients undergoing thoracotomy lung surgery may not be conclusively confirmed due to small sample sizes and lack of comparison with control groups. Therefore, future studies should involve randomized controlled trials with control groups and compare respiratory training with different types of devices.

The effectiveness of respiratory training with PEP devices in patients undergoing thoracotomy lung surgery may not be conclusively confirmed due to the small sample size and the absence of a control group. Additionally, the variability in the length of hospital stays among participants resulted in differing durations of intervention, which may have influenced the outcomes. Future research should consider conducting randomized controlled trials with larger sample sizes, including control groups, and comparing the effectiveness of various types of respiratory training devices.

Future study

Further randomized controlled trials with larger sample sizes and control groups including comparisons with patients receiving conventional chest physiotherapy alone are warranted to confirm the efficacy of positive expiratory pressure breathing in post-thoracotomy patients.

Practical implications

Integrating positive expiratory pressure (PEP) breathing at 15 cmH_2O starting on postoperative day 2 with conventional chest physiotherapy (airway clearance, breathing exercises, incision support, chest wall mobilization, and daily walking) provides a safe and accessible approach to support postoperative recovery of lung expansion and shoulder range of motion after thoracotomy. Visual feedback from water bubbling may encourage patient engagement, while other respiratory

training devices capable of delivering appropriate, adjustable expiratory resistance can also be applied in clinical practice. Delivering these exercises alongside adequate pain management and early rehabilitation can help alleviate movement and breathing restrictions during hospitalization.

Conclusion

Continuous positive expiratory breathing with 15 cmH_2O, 15 breaths per set, 12 sets per day for 5-10 days alongside a conventional chest physiotherapy program demonstrates positive effects on lung expansion and shoulder range of motion in thoracotomy patients. Further studies should compare with patients receiving only conventional physiotherapy or a control group.

Ethical approval

Ethical approval was obtained from the Human Research Ethics Committee, Faculty of Medicine, Prince of Songkla University (REC 56-005-11-82), and written informed consent was collected from all participants before enrollment.

Declaration of generative AI and AI-assisted technologies

During the preparation of this manuscript, the authors used OpenAI (GPT-6) to assist with grammar checking, language editing, and the generation of the graphical abstract. All AI-generated outputs were carefully reviewed and edited by the authors, who take full responsibility for the content of the published article.

Funding

This study did not receive any funding or financial support.

Conflict of interest

There were no conflicts of interest in this study.

CRediT authorship contribution statement

Saikaew Chuachan: conceptualization, methodology, validation, investigation, data curation, writing-original draft, review and editing, visualization, project administration; **Pattamar Phadermpol:** conceptualization, methodology, contributed to data collection; **Supalak Abuwa:** conceptualization, methodology, contributed to data collection; **Porraporn Sriwannawit**: validation, visualization, writing-review and editing; **Jatuporn Jaturawanit:** contributed to data collection; **Voravit Chittithavorn:** contributed to data collection.

Acknowledgements

We are thankful to all the patients who participated in this study.

References

[1] Ambrosino N, Gabbrielli L. Physiotherapy in the perioperative period. Best Pract Res Clin Anaesthesiol. 2010; 24(2):283-9. doi: 10.1016/j.bpa.2010.02.003.

[2] Ziyade S, Baskent A, Tanju S, Toker A, Dilege S. Isokinetic muscle strength after thoracotomy: standard vs. muscle-sparing posterolateral thoracotomy. Thorac Cardiovasc Surg. 2010; 58(5): 295-8. doi: 10.1055/s-0030-1249829.

[3] Nomori H, Horio H, Fuyuno G, Kobayashi R, Yashima H. Respiratory muscle strength after lung resection with special reference to age and procedures of thoracotomy. Eur J Cardiothorac Surg. 1996; 10(5): 352-8. doi: 10.1016/s1010-7940(96)80094-7.

[4] Ayed AK, Bazerbashi S, Chandrasekaran C, Sukumar M, Jamaleddin H. Pulmonary complications following major lung resection for benign and malignant lung diseases. Med Princ Pract. 2006; 15(2): 114-9. doi: 10.1159/000090915.

[5] Borges-Santos E, Genz ICH, Longo AF, Hayahsi D, Gonçalves CG, Bellinetti LM, *et al*. Pulmonary function,respiratory muscle strength and quality of life in patients submitted to elective thoracotomies. Rev Col Bras Cir. 2012; 39(1): 4-9. doi: 10.1590/s0100-69912012000100003.

[6] Urell C, Emtner M, Hedenström H, Tenling A, Breidenskog M, Westerdahl E. Deep breathing exercises with positive expiratory pressure at a higher rate improve oxygenation in the early period after cardiac surgery - a randomised controlled trial. Eur J Cardiothorac Surg. 2011; 40(1): 162-7. doi: 10.1016/j.ejcts.2010.10.018.

[7] Reeve J. Physiotherapy interventions to prevent postoperative pulmonary complications following lung resection. What is the evidence? What is the practice? N Z J Physiother. 2008; 36(3): 118-30.

[8] Brooks-Brunn J. Postoperative atelectasis and pneumonia. Heart Lung. 1995; 24(2): 94-115.

[9] Sehlin M, Öhberg F, Johansson G, Winsö O. Physiological responses to positive expiratory pressure breathing: a comparison of the PEP bottle and the PEP mask. Respir Care. 2007; 52(8): 1000-5.

[10] Varela G, Novoa NM, Agostini P, Ballesteros E. Chest physiotherapy in lung resection patients: state of the art. Semin Thorac Cardiovasc Surg. 2011; 23(4): 297-306. doi: 10.1053/j.semtcvs.2011.11.001.

[11] Renault JA, Costa-Val R, Rossetti MB. Respiratory physiotherapy in the pulmonary dysfunction after cardiac surgery.Rev Bras Cir Cardiovasc. 2008; 23(4): 562-9. doi: 10.1590/s0102-76382008000400018.

[12] Örman J, Westerdahl E. Chest physiotherapy with positive expiratory pressure breathing after abdominal and thoracic surgery: a systematic review. Acta Anaesthesiol Scand. 2010; 54(3): 261-7. doi: 10.1111/j.1399-6576.2009.02143.x.

[13] Westerdahl E, Lindmark B, Almgren SO, Tenling A. Chest physiotherapy after coronary artery bypass graft surgery - a comparison of three different deep breathing techniques. J Rehabil Med. 2001; 33(2):

79-84. doi: 10.1080/165019701750098920.
[14] Fagevik Olsén M, Wennberg E, Johnsson E, Josefson K, Lönroth H, Lundell L. Randomized clinical study of the prevention of pulmonary complications after thoracoabdominal resection by two different breathing techniques. Br J Surg. 2002; 89(10): 1228-34. doi: 10.1046/j.1365-2168.2002.02207.x.
[15] Watchie J. Cardiovascular and pulmonary physical therapy: a clinical manual. 2nd ed. St. Louis (MO): Saunders; 2009. p. 334.
[16] Miranda APB, de Souza HCD, Santos BFA, Abrão J, Cipriano FG, de Oliveira AS, et al. Bilateral shoulder dysfunction related to the lung resection area after thoracotomy. Medicine (Baltimore). 2015; 94(44): e1927. doi: 10.1097/MD.0000000000001927.
[17] Chuachan S, Reechaipichitkul W, Jones C. Effects of inspiratory muscle training using a new breathing device (BreatheMAX) for 7 days in patients with mechanical ventilator dependence: a pilot study of randomized controlled trial. J Med Tech Phys Ther. 2011; 23(2): 165-76. (in Thai).
[18] Jones CU, Kluayhomthong S, Chaisuksant S, Khrisanapant W. Breathing exercise using a new breathing device increases airway secretion clearance in mechanically ventilated patients. Heart Lung. 2013; 42(3): 177-82.doi: 10.1016/j.hrtlng.2012.12.009.
[19] Gosselink R, Schrever K, Cops P, Witvrouwen H, De Leyn P, Troosters T, et al. Incentive spirometry does not enhance recovery after thoracic surgery. Crit Care Med. 2000; 28(3): 679-83. doi: 10.1097/00003246-200003000-00013.
[20] Overend TJ, Anderson CM, Lucy SD, Bhatia C, Jonsson BI, Timmermans C. The effect of incentive spirometry on postoperative pulmonary complications: a systematic review. Chest. 2001; 120(3): 971-8. doi: 10.1378/chest.120.3.971.
[21] Sengupta S. Post-operative pulmonary complications after thoracotomy. Indian J Anaesth. 2015; 59(9): 618-26.doi: 10.4103/0019-5049.165852.
[22] DeTurk WE, Cahalin LP. Cardiovascular and pulmonary physical therapy: an evidence-based approach. 2nd ed. New York: McGraw-Hill; 2011. p. 518.
[23] Pryor JA, Prasad AS. Physiotherapy for respiratory and cardiac problems: adults and paediatrics. 4th ed. Edinburgh:Churchill Livingstone; 2008. p. 149-53.
[24] Westerdahl E, Lindmark B, Eriksson T, Friberg Ö, Hedenstierna G, Tenling A. Deep-breathing exercises reduce atelectasis and improve pulmonary function after coronary artery bypass surgery. Chest. 2005; 128(5): 3482-8. doi: 10.1378/chest.128.5.3482.
[25] Weissman C. Pulmonary function after cardiac and thoracic surgery. Anesth Analg. 1999; 88(6): 1272-9. doi: 10.1097/00000539-199906000-00014.
[26] Leelarungrayub D. Chest mobilization techniques for improving ventilation and gas exchange in chronic lung disease.In: Ong KC, editor. Chronic obstructive pulmonary disease - current concepts and practice. Rijeka: InTech; 2012. p.408-10. doi: 10.5772/38219.
[27] Gerner P. Post-thoracotomy pain management problems. Anesthesiol Clin. 2008; 26(2): 355-vii. doi: 10.1016/j.anclin.2008.01.007.
[28] Blichfeldt-Eckhardt MR, Andersen C, Ørding H, Licht PB, Toft P. From acute to chronic pain after thoracic surgery:the significance of different components of the acute pain response. J Pain Res. 2018; 11: 1541-8. doi: 10.2147/JPR.S161303.
[29] Li WWL, Lee RLM, Lee TW, Ng CSH, Sihoe ADL, Wan IYP, et al. The impact of thoracic surgical access on early shoulder function: video-assisted thoracic surgery versus posterolateral thoracotomy. Eur J Cardiothorac Surg. 2003; 23(3): 390-6. doi: 10.1016/s1010-7940(02)00795-9.
[30] Reeve J, Stiller K, Nicol K, McPherson KM, Birch P, Gordon IR, et al. A postoperative shoulder exercise program improves function and decreases pain following open thoracotomy: a randomized trial. J Physiother. 2010; 56(4): 245-52. doi: 10.1016/s1836-9553(10)70007-2.