Journal of Associated Medical Sciences 2025; 58(2): 314-321

JAMS
Journal of Associated Medical Sciences

Scopus Indexed & Thai-Journal Citation Index Centre (TCI)

Journal of Associated Medical Sciences

Journal homepage: https://www.tci-thaijo.org/index.php/bulletinAMS/index

# The applications of three-dimensional computed tomography images of the greater sciatic notch for sex determination in forensic anthropology aspect in Thai population

**Apisara Supthaveethanakij, Pongpon Traithepchanapai, Akarawin Chantakon, Pagparpat Varrathyarom***

*Department of Forensic Medicine, Faculty of Medicine, Chulalongkorn University, Bangkok, Thailand.*

**ARTICLE INFO**

*Article history:*
*Received 16 January 2025*
*Accepted as revised 10 April 2025*
*Available online 17 April 2025*

*Keywords:*
*Greater sciatic notch, pelvis, postmortem computed tomography (PMCT), sex determination, Thai population.*

**ABSTRACT**

**Background:** The identification of highly decomposed corpses or skeletons remains a significant challenge for forensic medical examiners. The pelvic bone, recognized for its reliability in sex determination, is frequently utilized through visual assessment as an initial step in such cases. However, the subjectivity of this method has prompted research into more accurate and objective approaches than traditional anatomical morphological evaluations.

**Objective:** The research was aimed to identify practical osteometric parameters of the greater sciatic notch, measured using a postmortem computed tomographic (PMCT) program, that have significant differences between male and female adults and provide high accuracy for sex determination in the Thai population. In addition, equation with high accuracy for sex determination using discriminant function analysis (DFA) was also developed.

**Materials and methods:** This study analyzed 385 Thai adults aged over 20, whose postmortem computed tomography (PMCT) scans included the hip region with an intact greater sciatic notch. The sample comprised 129 females and 256 males. The analyzed 6 osteometric parameters include *two distances*: PIIS-IS; the distance between the posterior inferior iliac spine (PIIS) and the ischial spine (IS), PIIS-SP; the distance between PIIS and Separating point (SP), a ratio of PIIS-SP to PIIS-IS (PIIS- SP/PIIS-IS), and *three angles*: Angle between planes passing PIIS and IS, and PIIS and DP (PIISA); Angle between planes passing PIIS and DP, and IS and DP (GSNA) and Posterior part when the GSNA is divided by DP-SP plane (GNSPA). Discriminant function analysis was used for data evaluation.

**Results:** Three-dimensional measurements of the greater sciatic notch demonstrated high reliability, with intra- and inter-observer ICC values exceeding 0.8 ($p<0.05$). All five measurements and the ratio achieved over 92% accuracy in multivariate analysis for cross-validated cases. DFA confirmed the suitability of all parameters for inclusion in the discriminant equation, which provided thresholds for sex determination: D<-1.03 indicated male, D>2.04 indicated female, and intermediate values were indeterminate, accounting for 67.73% of population variance.

**Conclusion:** This study demonstrates that all the selected measurements of the greater sciatic notch can effectively differentiate between male and female adults through the application of discriminant function with an overall accuracy of 92%.

## Introduction

In forensic autopsy, as outlined in Section 154 of the Criminal Procedure Code,[1] forensic physician must determine the deceased's identity, the timing and location of the incident, and the cause and manner of death. While a complete dissection is not always necessary if sufficient information is available, identification becomes challenging in cases involving decomposed corpses or skeletal remains. The Central Institute of Forensic Science

* **Corresponding contributor.**
**Author's Address:** *Department of Forensic Medicine, Faculty of Medicine, Chulalongkorn University, Bangkok, Thailand.*
**E-mail address:** Pagparpat.v@gmail.com
**doi:** 10.12982/JAMS.2025.066
**E-ISSN:** 2539-6056

in Thailand reported 1,420 unidentified corpses between 2014 and 2023, with 102 unidentifiable due to decomposition.[2] In 2023, approximately 13.3% of corpses could not have their sex determined.

Several methods have been applied in past decades using different parts of the bony structure to find the most reliable and practical method for sex determination. While anatomical morphology is commonly used for convenience, it is subjective and affected by postmortem changes.[3] Metric measurements offer more accuracy but can be challenging to maintain consistency in correcting the position and still can be affected by postmortem changes. Geometric analyses using 3D imaging are the most precise method and allow for data preservation without alteration; however, they require advanced technology, limiting their accessibility in some contexts.

Computed tomography (CT) is an imaging modality generating detailed 3D images from consecutive two-dimensional axial slices for medical diagnosis. It is increasingly utilized due to its efficiency, durable data storage, rapid results, and non-invasive autopsy capabilities. Since its introduction in Thailand in 2016, PMCT has enhanced forensic investigations by enabling comparisons with antemortem data and providing detailed imaging of structures that are difficult to assess through traditional autopsies.[3]

Accurate sex estimation relies on population-specific data, which becomes more reliable after puberty (ages 15-18) when skeletal features have been fully developed. By age 20, the skeleton is typically fully fused, allowing for nearly 100% accuracy using the entire skeleton, 98% with the skull and pelvis, 95% with the pelvis alone, and 92% with the skull alone.[4,11]

Although the pelvic bone is claimed to be the most accurate sex-determination tool, owing to its parturition function, the pubis tends to be fragile and poorly preserved.[5] However, the greater sciatic notch (GSN) remains a reliable indicator as anatomically, the greater sciatic notch is deep and narrow in males and wider in females. Also, due to its robust cortical bone, the GSN remains highly resistant to damage or degradation, achieving an accuracy of 80-83% in sex classification using visual, angular, and geometric morphometric assessment across various studies.[6,7,8]

Knecht's study[9] also demonstrates that the accuracy increases when considering the deepest point of the greater sciatic notch.[9] The Diagnose Sexuelle Probabiliste (DSP) method, using ten measurements from a global dataset,[10,12] achieves an accuracy ranging from 86% to 99% in different ethnic groups, with the lowest accuracy in the African group. Furthermore, using the greater sciatic notch alone, accuracy ranges from 70% to 93%. Furthermore, using the greater sciatic notch alone, accuracy ranges from 70% to 93%.

In a 2006 study in France by Christophe Boulay and colleagues, pelvic symmetry was examined using 3D measurements from 12 common anatomical reference points. The study revealed that the right and left greater sciatic notches have nearly identical anatomical dimensions, making them suitable for use as standard parameters in our study.[13]

There was also a study conducted in Thailand that assessed three parameters —greater sciatic notch depth, width, and posterior segment distance—using a digital Vernier caliper on 100 dry adult bone samples for sex determination.[14] Using descriptive statistics and discriminant analysis, the measures showed high accuracy, ranging from 92% to 96% with the maximum width (MW), width-to-depth ratio (MW/MD), and width-to-posterior segment ratio (MW/PS).

In Korea, 2018, the visual scoring method developed by Walker,[15] struggled with accuracy due to age and ethnic overlaps. making it difficult to distinguish between males and females in the intermediate zone. Kim Dong-Ho and colleagues employed a metric method on 3D models derived from radiographic images, ensuring reproducible and stable measurement of the greater sciatic notch with over 85% accuracy.[15] Measurements related to the posterior part of the greater sciatic notch showed high accuracy (93.1%).

This study aims to establish a practical method for sex determination using pelvic measurements from PMCT, focusing on Thai population data. Six osteometric parameters are identified: three distances (PIIS-IS, PIIS-SP, PIIS-SP/PIIS-IS ratio) with 78.70%-90.10% accuracy and three angles (PIISA, GSNA, GNSPA) with 90.10%-93.10% accuracy. These parameters were selected for their high accuracy from the study of Kim *et al*.[15] The goal is to find convenient PMCT parameters for effective sex determination that avoid time-consuming procedures like tissue removal.

## Materials and methods

### *Materials*

*Study design and target population*

This retrospective analytic study examined deceased Thai adults aged 20 years or older who underwent forensic autopsies at the Department of Forensic Medicine, Chulalongkorn University, in 2023. Sex and age were verified using national identity cards. Cases with pelvic bone abnormalities, such as defects, trauma, or metallic objects that could affect PMCT image interpretation, were excluded from the analysis.

*Sample size acquisition*

The sample size, calculated using Cochran's formula, comprised 385 cases.[17] To reduce the imbalance in the female-to-male ratio from the total of 622 cases, all 129 eligible female cases meeting the inclusion-exclusion criteria were included. From the remaining 480 male cases, 256 were randomly selected using the random function in Microsoft Excel 2019 to ensure unbiased sampling.[16]

The Cochran's formula used for sample size calculation: n=sample size, p=proportion of the population (0.5), Z=confidence level (1.96), e=allowable error (0.05).[17]

$$n = \frac{Z^2 p(1-p)}{e^2}$$

***Methods***

*Informed consent process*

This retrospective study analyzed PMCT images routinely collected at the Department of Forensic Medicine, Faculty of Medicine, Chulalongkorn University. The identity and specific information of the deceased were kept confidential and cannot be used to identify further personal information, so informed consent from the deceased relatives was not obtained in this study.

The study was approved by the Research Ethics Committee of the Faculty of Medicine, Chulalongkorn University, receiving an exemption from ethics consideration with Institutional Review Board (IRB) number 665/67 and Certificate of Exemption (COE) number 051/2024.

*Ethical consideration*

During the procedures, only certain information such as sex, age, nationality, and the pelvic PMCT images was utilized. Other personal details, including the deceased's name, were kept confidential, with data access restricted to the Forensic Department at Chulalongkorn University.

*Standard plane and anatomical landmark creation*

PMCT scans were performed using a GE Revolution EVO CT machine with standardized parameters (1x64x0.625 mm collimation, 120 kV, 200 mA, 0.8 s rotation time). The AW server 3.2 ext. 4.0 SW AND DOCS for Virtual AW server (GE Healthcare, France) was used to generate and evaluate the 3D PMCT images. To standardize measurements, the pelvic bone was aligned in an anterior view, with the pubic symphysis positioned along the midline of the lumbar and sacral spine. Then rotated horizontally 60° counterclockwise and visualized to maximize the visibility of the greater sciatic notch and ensure consistency in osteometric measurements (Figure 1). Key anatomical landmarks—Posterior Inferior Iliac Spine (PIIS), Deepest Point (DP), Ischial Spine (IS), and Sciatic Process (SP)—were identified after removing the sacral region for clarity (Figure 2 and 3). The abbreviation of each anatomical landmark and measurement was shown below (Table 1).

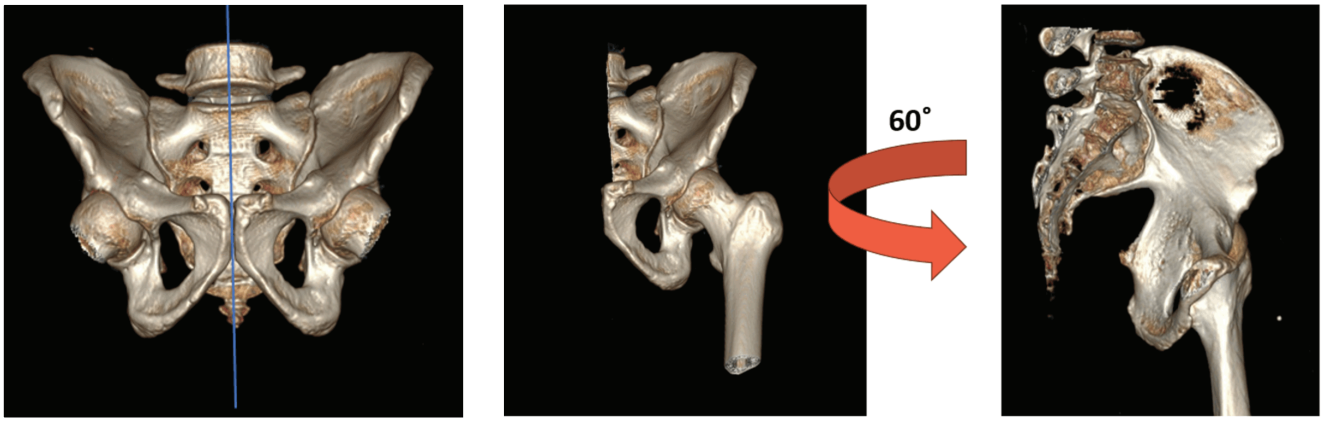


***Figure 1****. Demonstrates the adjustment axis and rotates it to the optimal angle of the left greater sciatic notch.*

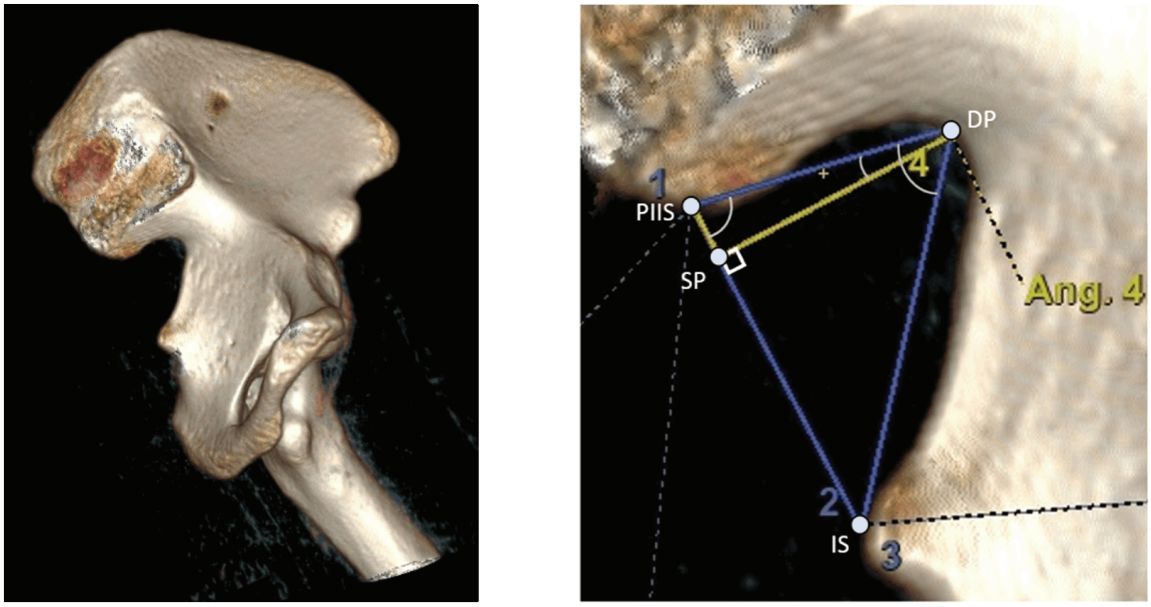


***Figure 2****. Clear margin of the left greater sciatic notch after removing the sacral part and marks the anatomical points before the osteometric measurements were done.*

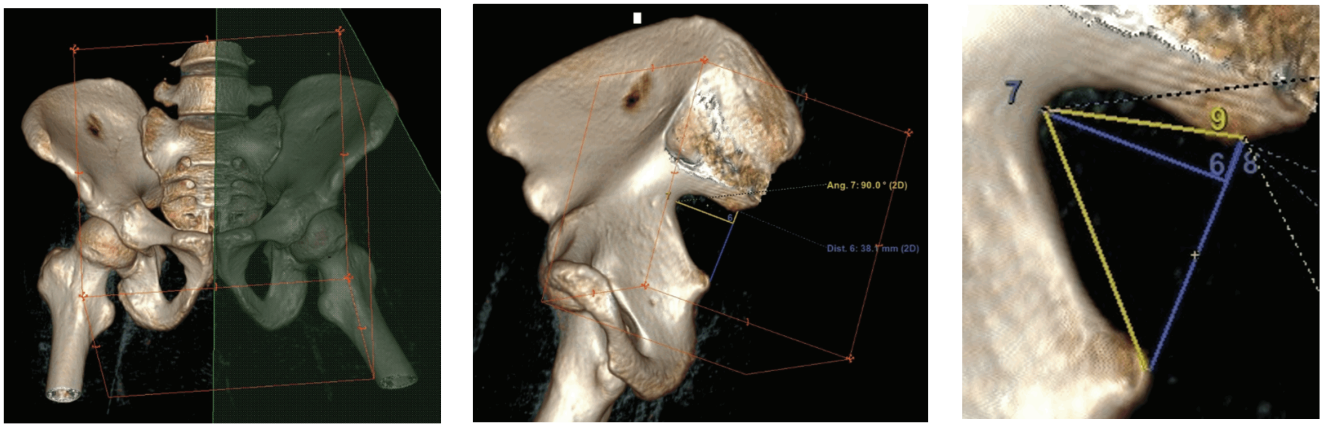


***Figure 3**. Compares the same procedures with the other side, the right greater sciatic notch.*

**Table 1**. Definition of anatomical landmarks and measurements.

| | |
|---|---|
| **Landmarks** | |
| PIIS | Posterior inferior iliac spine |
| DP | The deepest point of the greater sciatic notch |
| IS | Ischial spine |
| Sp | Separating point: the point where perpendicular line from DP meets the PIIS-IS line |
| **Distances** | |
| PIIS-IS | Distance between PIIS and IS. |
| PIIS-SP | Distance between PIIS and SP. |
| **Angles** | |
| PIISA | The angle between planes passing PIIS and IS, and PIIS and DP. The angle between planes |
| GSNA | passing PIIS and DP; and IS and DP. |
| gsnpa | The posterior part where the GSNA is divided by the DP-SP plane. |

*Comparative Analysis*

Randomly selected 20 cases, using the random function in Microsoft Excel 2019,[16] were used to assess measurement differences between the left and right hip bones through a paired t-test. To evaluate inter-observer and intra-observer reliability, the Intra-class Correlation Coefficient (ICC) was employed. Intra-observer error was assessed by a single author (AS), who measured 20 randomly selected samples, comprising 10 females and 10 males, twice with six months apart. For inter-observer error, we compared the results of two authors — the principal investigator, a third-year forensic resident (AS), and a forensic staff in the Department of Forensics, Chulalongkorn University (AC).

*Statistical analysis*

Statistical analyses were performed using SPSS software (version 29.0.2.0, SPSS, Thailand). Discriminant function analysis (DFA) calculated each parameter using a weight matrix, with Canonical discrimination functions assessed through Eigenvalue and Canonical correlation values to determine the strength of the correlation between the derived equation and population-specific data.

## Results

A comparative analysis was performed using 20 randomly selected cases to assess measurement differences between the left and right hip bones. Paired t-tests showed no statistically significant differences across all parameters (*p* values: 0.928, 0.937, 0.885, 0.802, 0.519, and 0.689) (Table2). Consequently, the left hip bone was selected as the reference side for further measurements. This selection aligns with anthropological standards favoring the non-dominant side, typically the left, to minimize the impact of degenerative changes from overuse, ensuring greater measurement reliability.[7]

**Table 2**. Comparison of all parameters between left and right greater sciatic notch.

| Left and right comparison | Paired differences | | | | | *p* value |
|---|---|---|---|---|---|---|
| | Mean | SD | SE mean | 95% CI of the difference | | |
| | | | | Lower | Upper | |
| PIIS-IS | 0.0060 | 0.29396 | 0.06573 | -0.13158 | 0.14358 | 0.928 |
| PIIS-SP | -0.0065 | 0.36325 | 0.08123 | -0.17651 | 0.16351 | 0.937 |
| PIIS-SP/PIIS-IS ratio | 0.0030 | 0.09125 | 0.02041 | -0.03971 | 0.04571 | 0.885 |
| PIISA | 0.3350 | 5.89355 | 1.31784 | -2.42327 | 3.09327 | 0.802 |
| GSNA | -0.8050 | 5.47929 | 1.22521 | -3.36939 | 1.75939 | 0.519 |
| GSNPA | -0.3950 | 4.34093 | 0.97066 | -2.42662 | 1.63662 | 0.689 |

The results of intra- and inter-observer error assessments, detailed in Table 3 ($p<0.05$), indicate that 3D measurements of the greater sciatic notch demonstrate good to excellent reliability, with ICC values exceeding 0.8 for repeated measurements. Accuracy estimation of all measurements was conducted through multivariate analysis, revealing that all five measurements and one ratio achieved high accuracy. Discriminant function analysis showed that the absolute values of the structure matrix for all parameters exceeded 0.3, confirming their suitability for inclusion in the discriminant equation. Among these, the PIIS-SP parameter was identified as the best predictor for sex determination (Table 4).

**Table 3**. Intra- and Inter-observer error of direct measurements using ICC value.

| | PIIS-IS | PIIS-SP | PIIS-SP / PIIS-IS ratio | PIISA | GSNA | GSNPA |
|---|---|---|---|---|---|---|
| Intra-rater ICC | 0.978 | 0.992 | 0.987 | 0.980 | 0.984 | 0.988 |
| Inter-rater ICC | 0.946 | 0.919 | 0.861 | 0.937 | 0.991 | 0.944 |

**Table 4**. Discriminant function analysis of all parameters.

| Measurements | Total | | Male | | Female | | Structure matrix | Standardized canonical discriminant function coefficients |
|---|---|---|---|---|---|---|---|---|
| | Mean | SD | Mean | SD | Mean | SD | | |
| **Distance** | | | | | | | | |
| PIIS-IS | 4.33 | 2.04 | 4.10 | 2.44 | 4.81 | 0.53 | 0.559 | -0.394 |
| PIIS-SP | 0.84 | 0.71 | 0.52 | 0.55 | 1.47 | 0.57 | 0.553 | 1.231 |
| **Ratio** | | | | | | | | |
| PIIS-SP / PIIS-IS | 0.19 | 0.15 | 0.13 | 0.14 | 0.30 | 0.10 | 0.455 | -1.697 |
| **Angle** | | | | | | | | |
| PIISA | 74.61 | 13.05 | 81.14 | 9.69 | 61.64 | 8.31 | -0.620 | -0.131 |
| GSNA | 64.90 | 13.02 | 57.44 | 7.38 | 79.69 | 8.27 | 0.944 | 0.809 |
| GSNPA | 15.44 | 13.07 | 8.89 | 9.63 | 28.49 | 8.32 | 0.695 | 0.673 |

Using discriminant function analysis (DFA) from the weight matrix, Canonical discrimination functions were used in the study with the Eigenvalue of 2.106 and Canonical correlation value of 0.823, which implied that the obtained equation could correlate with 67.73% of this population due to the R-square value of 0.6773. The obtained discriminant equation (D) is as shown below. The average D value for the male group is -1.028, while for the female group is 2.039, which indicates that if the D value is lower than -1.03, the predicted sex is male, and if the D value is greater than 2.04, the expected sex is female. When the D value falls between -1.03 and 2.04, the predicted sex is uncertain.

$$D = 2.205(PIIS - SP) + 0.105(GSNA) + 0.073(GSNPA) - 0.013(PIISA) - 0.788(PIIS - IS) - 13.657(PIIS - SP|PIIS - IS\ ratio) - 2.970$$

The discriminant function equation. The information obtained from the graph's discriminant function distribution offers additional evidence to support greater sexual differences. The average D value is -1.028 in males and 2.039 in females (Figure 4).

According to the validation process, accuracy is determined using a discriminant function derived from all cases except the one being classified. The predicted group membership achieves an accuracy of 92.5% in cross-validated grouped cases.

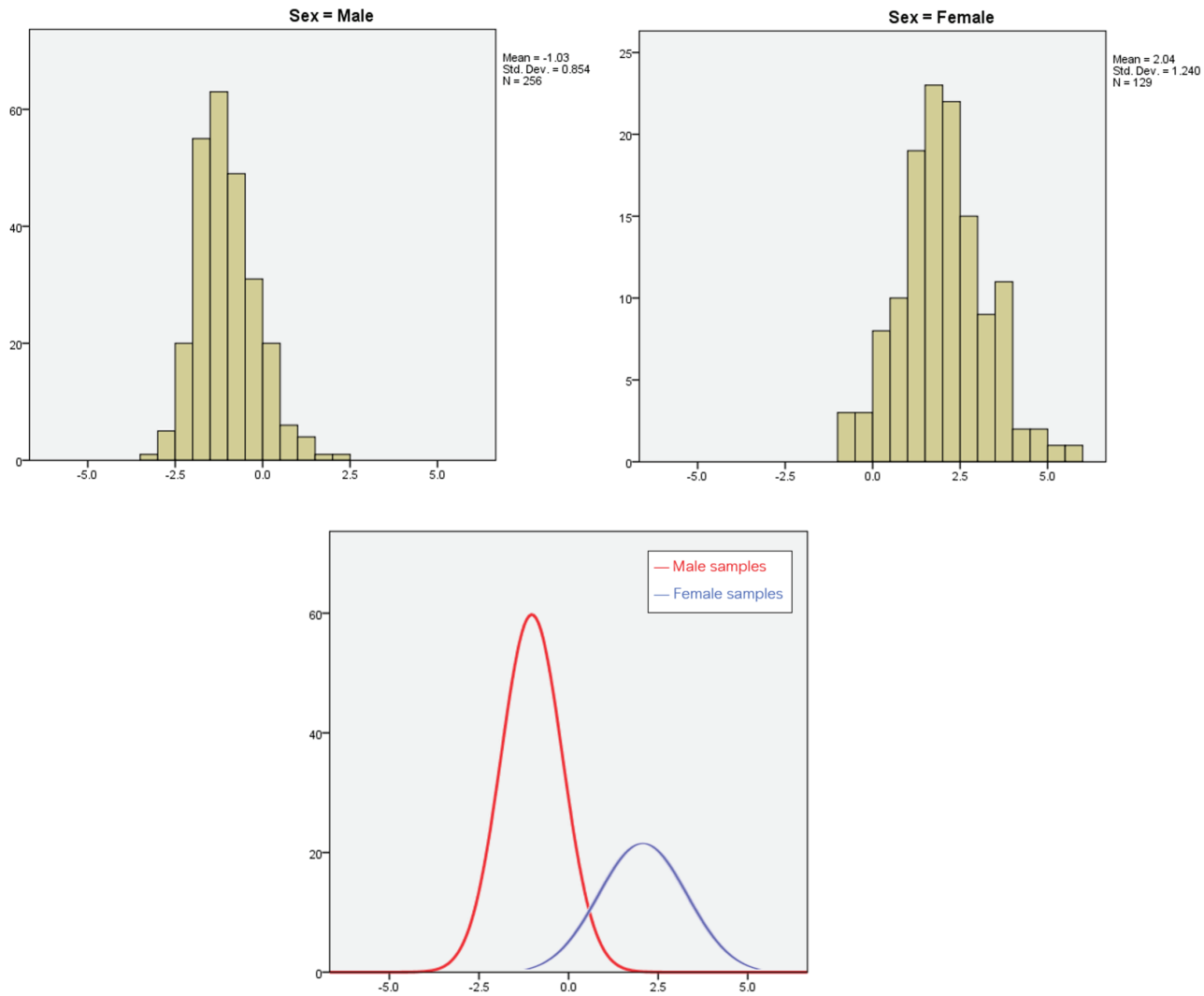


***Figure 4**. The discriminant function graphs comparing male and female cases with the average D value is -1.028 in males and 2.039 in females.*

## Discussion

Analysis of the greater sciatic notch parameters (PIIS-IS, PIIS-SP, the ratio, PIISA, GSNA, and GSNPA) using PMCT images achieved an overall accuracy of 92.5% for sex determination via the discriminant function equation. The results reflect population-specific characteristics while aligning fundamental anthropological principles and findings from other population studies.

In the sample size acquisition process to decrease the selection bias by using the Mersenne Twister algorithm, the random function in Microsoft Excel 2019 (RAND) is considered a sufficient and reliable random number generator.[16] Furthermore, to ensure accuracy and consistency, 3D modeling was employed to verify anatomical landmarks and establish reference planes, addressing challenges in landmark identification and enhancing measurement reliability. This method provides a guide for researchers to accurately identify landmarks and perform precise measurements based on these reference planes verified through computational tools.

Reproducibility was confirmed with high intra- and inter-observer reliability, yielding ICC values exceeding 0.98 and 0.86, respectively (Table 3). The findings for the Thai population's greater sciatic notch are consistent with data from other populations, supporting the applicability of prediction equations across diverse groups.

As shown in Table 5, this study achieved the highest accuracy among PMCT-based sex differentiation methods while using the fewest parameters. Its accuracy, exceeding 90%, is comparable to studies using dry bone measurements, supporting its practicality due to ease of data collection. Additionally, since the results for the Thai population align with findings from other ethnic groups in previous studies, it can be concluded that this approach is applicable to other populations as well.

Radiological imaging, used for data collection, offers a non-invasive method and facilitates the convenient archiving of skeletal data. The subsequent application of 3D modeling permits reproducible measurements and enables the exploration of a wider range of measurement techniques. However, this method has inherent limitations, such as the need for a CT imaging system and the necessary training to operate it. Despite these challenges, the accessibility of such facilities greatly enhances the utility of skeletal collections, providing researchers with expanded opportunities for data analysis through 3D measurements.

Based on the findings of this study, the greater sciatic notch is a highly reliable tool for sex determination. Future research should investigate the applicability of this parameter across different ethnicities to evaluate its effectiveness and generalizability.

### *Limitations*

This study is limited by the operator-dependent measurement procedures, particularly in assessing distances and angles within the greater sciatic notch, which may introduce inconsistencies and affect accuracy. Despite standardized protocols, some subjectivity persists. Additionally, anatomical variations in pelvic morphology, influenced by genetic and environmental factors, may lead to overlapping measurements between sexes, reducing the reliability.

**Table 5**. Comparison of the accuracy of sex determination with other studies.

| Study | Population | Material | Variables | N | accuracy |
|---|---|---|---|---|---|
| This study | Thai | PMCT 3D images | GSN (6 parameters) | 385 | 92.5% |
| Kim *et al*.[15] | Korean | PMCT 3D images | GSN (17 parameters) | 202 | 78.7-93.1% |
| Soltani *et al*.[18] | Iran | PMCT 3D images | GSN (10 parameters) | 237 | 89.5-90.3% |
| Gomez-Valdes *et al*.[6] | Mexican | Dry bones images:<br>Visual scoring<br>Geometric morphometric measurement | GSN<br>(2 landmarks and 30 semi-landmarks) | 130 | <br>68.5%<br>82.3% |
| Bruzek *et al*.[19] | Multiethnic (American, African, Asian, European) | Dry bones geometric measurement | Whole pelvis<br>10 parameters<br>8 parameters<br>4 parameters | 2,040 | <br>99.65%<br>99.65%<br>99.53% |
| Knecht *et al*.[9] | French | Dry bones geometric measurement | GSN (16 parameters) | 60 | 92-97% |
| Boonsonti S.[14] | Thai | Dry bones geometric measurement | GSN (5 parameters) | 200 | 83-96% |

## Conclusion

This study offers a comprehensive analysis of the greater sciatic notch through 3D measurement, providing valuable population-specific data. Our findings demonstrate that 3D measurement techniques yield results that are applicable to samples from the same population, offering a more objective evaluation compared to traditional anatomical assessments based on visual methods for sex determination. This supports the broader use of 3D measurement in anthropological research and when examining dry bone specimens, thereby reducing bias.

Additionally, we confirmed the presence of sexual dimorphism in the greater sciatic notch within the Thai population, which aligns with findings from other populations. The results of this study aim to serve as a foundation for future research that compares different populations and enhances our understanding of population-specific skeletal characteristics.

## Conflict of interest statement

The authors declare no conflict of interest.

## Funding

This research received no specific grant from public, commercial, or non-profit funding agencies.

## Acknowledgements

We would like to thank the forensic radiologic specialized staff in the Forensic Department of Chulalongkorn University, the computed tomographic technician, and the statistician from the research affairs in the Faculty of Medicine Chulalongkorn University. Language assistance for this research was provided by ChatGPT, a language model developed by OpenAI.

## References

[1] Criminal Procedure Code, Section 154. Act Promulgating the Criminal Procedure Code, BE 2477 (1934) [Internet]. Available from: https://www.icj.org/wp-content/uploads/2012/12/Thailand-Criminal-Procedure-Code-1934-2008-eng.pdf

[2] Thailand Missing Person Information Center. Statistics of Anonymous corpse in 2023 [Internet]. 2024 [cited 2024 Jan 25]. Available from: https://www.thaimissing.go.th/stat

[3] Buzug TM. Computed tomography. In: Kramme R, Hoffmann K-P, Pozos RS, editors. Springer handbook of medical technology. Berlin, Heidelberg: Springer Berlin Heidelberg; 2011. p. 311-42.

[4] Saukko PJ, Knight B. Knight's forensic pathology. 4th Ed. London: Hodder Arnold; 2015.

[5] Iscan MY, Steyn M. The human skeleton in forensic medicine. 3rd Ed. Springfield (IL): Charles C Thomas; 2013.

[6] Gómez-Valdés JA, Quinto-Sánchez M, Menéndez Garmendia A, Veleminska J, Sánchez-Mejorada G, Bruzek J. Comparison of methods to determine sex by evaluating the greater sciatic notch: visual, angular, and geometric morphometrics. Forensic Sci Int. 2012; 221(1-3): 156.e1-7. doi: 10.1016/j.forsciint.2012.04.027.

[7] White TD, Folkens PA. The human bone manual. Amsterdam: Elsevier Academic Press; 2005.

[8] Franklin D. Estimation of skeletal sex. Centre for Forensic Anthropology, The University of Western Australia, Australia: Elsevier Ltd; 2023.

[9] Knecht S, Nogueira L, Servant M, Santos F, Alunni V, Bernardi C, Quatrehomme G. Sex estimation from the greater sciatic notch: a comparison of classical statistical models and machine learning algorithms. Int J Legal Med. 2021;135(6):2603-13.

[10] Murial P, Bruzek J, Houet F, Cunha E. DSP: A tool for probabilistic sex diagnosis using worldwide variability in hip-bone measurements. BMSAP. 2005; 17(3-4): 3-4. doi: 10.4000/bmsap.1157

[11] Blake KA. An investigation of sex determination from the subadult pelvis: A morphometric analysis [dissertation]. Pittsburgh (PA): University of Pittsburgh; 2011.

[12] Walker PL. Greater sciatic notch morphology: Sex, age, and population differences. Am J Phys Anthropol. 2005; 127(4): 385-91. doi: 10.1002/ajpa.10422.

[13] Boulay C, Tardieu C, Benaim C, Bénaim J, Chavet P, Marty C, *et al*. Three-dimensional study of pelvic asymmetry on anatomical specimens and its clinical perspectives. J Anat. 2006; 209(1): 57-66. doi: 10.1111/j.1469-7580.2006.00513.x

[14] Boonsonti S. Greater sciatic notch in sex determination by the metric method. J Thai Justice Syst. 2022.

[15] Kim DH, Yoon HJ, Cho K, Oh JH. A comprehensive evaluation of the greater sciatic notch for sexual estimation through three-dimensional metric analysis using computed tomography models. J Leg Med. 2018; 35(1): 1-8. doi: 10.1016/j.legalmed.2018.09.006.

[16] John F. Analysing the Validity of Random Number Generators [Internet]. 2023 [cited 2025 Mar 5]. Available from: https://kurser.math.su.se/pluginfile.php/20130/mod_folder/content/0/Kandidat/2023/2023_12_report.pdf?forcedownload=1

[17] Koonkaew A. Choosing and using statistics and statistical analysis in research. Bangkok: Chulalongkorn University; 2023. p. 40-41.

[18] Soltani S, Momenzadeh S, Afshar P, Hoseini M, Ghaffari H, Aliakbarian M, *et al*. Evaluation of greater sciatic notch parameters in sex determination of hip bone by three-dimensional CT images. J Clin Diagn Res. 2018; 12(9): 1-5. doi: 10.7860/JCDR/2018/36428.11991.

[19] Bruzek J, Santos F, Dutailly B, Murail P, Cunha E. Validation and reliability of the sex estimation of the human os coxae using freely available DSP2 software for bioarchaeology and forensic anthropology. Am J Phys Anthropol. 2017; 164(2): 440-9. doi: 10.1002/ajpa.23282.