KDJ Khon Kaen University Dental Journal

Clinical Manifestations and Dental Management in a Pediatric Patient with Chromosome 22q11.2 Deletion Syndrome: A Case Report

Jinda Lertsirivorakul [1,] Duanghathai Iamviteevanitch [2] Khunton Wichajarn [3] Ajiravudh Subarnbhesaj [4]*

Case Report

Abstract

Objective: This report aims to describe the orofacial and dental manifestations, along with the comprehensive dental management, in a child diagnosed with 22q11.2 DS.

Case Presentation: A 4-year-old girl presented with multiple congenital anomalies, including complex cyanotic congenital heart disease, dysmorphic craniofacial features, bilateral complete cleft lip and palate, and anovestibular fistula. The patient also exhibited hypotonia, feeding and swallowing difficulties, hearing loss, hypernasal speech, and global developmental delay. The patient had previously undergone several major surgical interventions as part of her multidisciplinary management.

Clinical and radiographic examinations revealed multiple extensively carious teeth consistent with severe early childhood caries, along with malformation and agenesis of several developing permanent teeth. Owing to the patient's limited ability to cooperate, significant medical comorbidities, and extensive dental treatment needs, comprehensive oral rehabilitation under general anesthesia was provided. The procedure was completed successfully; however, the patient experienced a prolonged postoperative recovery. Following treatment, she was scheduled for regular dental and medical follow-up visits to ensure ongoing preventive care, monitoring, and long-term management.

Conclusion: Patients with 22q11.2 DS commonly have multiple underlying medical conditions and are at increased risk for orofacial anomalies and oral diseases. Dental care should begin early and be maintained throughout the patient's life. Successful management requires a collaborative, multidisciplinary approach involving specialized medical and dental professionals, supported by informed and engaged caregivers, to achieve optimal oral health and improve overall quality of life for these patients.

Keywords: Chromosome 22q11.2 deletion syndrome/ DiGeorge syndrome/ Velocardiofacial syndrome/ Cleft palate/ Tetralogy of Fallot

Received: *Sep 13, 2024*
Revised: *Aug 13, 2025*
Accepted: *Oct 24, 2025*

Introduction

Chromosome 22q11.2 deletion syndrome (22q11.2 DS) is one of the most common human microdeletion syndromes, with an estimated prevalence of 1 in 2,000 to 1 in 6,000 live births.[1] The majority of cases (90–95%) arise from a de novo germline mutation.[2] The true prevalence of the syndrome may be underestimated due to its variable expressivity, diagnostic challenges, and the absence of routine newborn screening.[3] Both males and females are equally affected.[4]

[1] *Faculty of Dentistry, Bangkokthonburi University.*
[2] *Dental Department, Banchang Hospital, Rayong.*
[3] *Division of Medical Genetics, Department of Pediatrics, Faculty of Medicine, Khon Kaen University.*
[4] *Department of Oral Biomedical Sciences, Faculty of Dentistry, Khon Kaen University.*
[*] *Corresponding author*

22q11.2 DS is caused by a microdeletion of approximately 3 million base pairs on the q11.2 region of chromosome 22 and follows an autosomal dominant inheritance pattern.[5] Currently, it is understood that 22q11.2 DS (MIM #611867) encompasses several conditions that were previously classified as distinct disorders, including DiGeorge syndrome (MIM #188400), velocardiofacial syndrome (MIM #192430), conotruncal anomaly face syndrome (MIM #217095), some cases of autosomal dominant Opitz G/BBB syndrome (MIM #145410), and Cayler cardiofacial syndrome (MIM #125520).[3,5]

The diagnosis of 22q11.2 DS can be made using fluorescence in situ hybridization (FISH), a molecular cytogenetic technique that uses fluorescently labeled DNA probes to detect and visualize specific DNA sequences on chromosomes.[6] However, newer and more sensitive diagnostic techniques, such as chromosomal microarray analysis (CMA) and multiplex ligation-dependent probe amplification (MLPA), are increasingly being used to detect deletions of various sizes and may replace FISH in the future.[5,7-8]

CMA, a genetic testing technique that scans the entire genome to identify missing or extra segments of genetic material, can detect small genetic alterations, including submicroscopic abnormalities that are too subtle to be detected by conventional karyotyping or FISH.[9] MLPA, a variation of the multiplex polymerase chain reaction (PCR), allows the simultaneous amplification of multiple DNA targets using only a single primer pair.[10]

Individuals with 22q11.2 DS exhibit a wide spectrum of clinical features, ranging from mild to severe. The most common manifestations include congenital heart defects—especially conotruncal malformations such as ventricular septal defect, tetralogy of Fallot, interrupted aortic arch, and truncus arteriosus—palatal abnormalities, distinctive craniofacial features, immune deficiencies due to thymic hypoplasia, hypoparathyroidism with resultant hypocalcemia, renal and gastrointestinal abnormalities, and central nervous system involvement. [5,7-8] These neurological features may lead to learning difficulties, intellectual disability, behavioral issues, and a high incidence of psychiatric disorders later in life[5,7-8] Additionally, affected children have a higher likelihood of developing attention deficit hyperactivity disorder (ADHD) and other neurodevelopmental disorders, including intellectual disability and autism spectrum disorder, which impair communication and social functioning.[3]

Other systemic manifestations may include respiratory problems, renal anomalies, hypocalcemia-induced seizures, thrombocytopenia, and gastrointestinal complications. Velopharyngeal insufficiency often results in recurrent otitis media, which can lead to conductive hearing loss. Skeletal anomalies, such as mild short stature, slender digits, and occasionally vertebral abnormalities, may also be observed.[3, 5]

The orofacial region is frequently affected in individuals with 22q11.2 DS. Mild facial dysmorphisms include a small mouth, malar flatness, ptosis, hypertelorism, epicanthal folds, narrow palpebral fissures, a prominent nasal root, a bulbous nasal tip with hypoplastic alae nasi, and slightly malformed ears. Common palatal anomalies include velopharyngeal insufficiency, submucous cleft palate, bifid uvula, and overt cleft palate. Several dental anomalies are frequently reported, such as enamel defects (both hypoplasia and hypomineralization), abnormal tooth morphology, tooth agenesis, and delayed eruption.[8,11-16] High prevalence of dental caries and gingival disease are also notable oral findings.[8]

Although 22q11.2 DS has been widely reported in medical literature, detailed descriptions of oral and dental manifestations remain relatively limited. Additionally, the multisystem involvement characteristic of this syndrome may complicate dental treatment planning and delivery. To date, few references have

addressed the dental management of patients with 22q11.2 DS. This report aims to describe the orofacial features and comprehensive dental management of a pediatric patient with 22q11.2 DS, with a focus on treatment under general anesthesia (GA).

Case Presentation

A 4-year-old girl from northeastern Thailand presented to the Pediatric Dentistry Clinic, Faculty of Dentistry, Khon Kaen University, with a chief complaint of multiple carious teeth. Her family history was unremarkable, with no known hereditary disorders or consanguinity. Both her parents and her twin brother were healthy.

Medical and dental history

The patient and her dizygotic twin brother were conceived via intracytoplasmic sperm injection (ICSI) when their parents were 35 and 38 years old, respectively. At 20 weeks of gestation, prenatal ultrasonography revealed a bilateral complete cleft lip and palate in the patient. Both twins were delivered prematurely by cesarean section at 35 weeks of gestation. At birth, the patient weighed 1,070 grams and measured 36 cm in length, placing her below the 3rd percentile for Thai children.

The patient required neonatal resuscitation and treatment for meconium aspiration syndrome. The patient exhibited multiple congenital anomalies, including dysmorphic craniofacial features, bilateral complete cleft lip and palate, complex cyanotic congenital heart disease—comprising tetralogy of Fallot, pulmonary atresia, patent ductus arteriosus, and patent foramen ovale—as well as an anovestibular fistula. Due to the presence of tetralogy of Fallot and neonatal hypocalcemia, a consultation with a clinical geneticist was conducted shortly after birth. Cytogenetic analysis showed a normal female karyotype (46,XX). However, FISH targeting the 22q11.2 region revealed a microdeletion, thereby confirming the diagnosis of chromosome 22q11.2 deletion syndrome. Additional complications developed over time, including hypotonia, feeding and swallowing difficulties, hearing loss, hypernasal speech, and global developmental delay.

The patient underwent multiple surgical interventions during early childhood. At 4 months of age, a right Modified Blalock-Taussig Shunt (MBTS) was placed using a polytetrafluoroethylene (PTFE) graft. At 7 months, the patient underwent a cutback procedure to correct an anovestibular fistula, followed by cheiloplasty and anal transposition at 8 months of age. Her first palatoplasty was performed at 18 months. At 2 years of age, bilateral myringotomy was conducted, and at 2 years and 10 months, a left MBTS was placed. At 3 years and 8 months, the patient underwent a second palatoplasty utilizing a facial artery musculomucosal (FAMM) flap; however, complete closure of the cleft palate could not be achieved due to insufficient tissue availability.

The patient experienced frequent episodes of constipation and recurrent infections, including respiratory tract infections (e.g., pneumonia), gastrointestinal infections (e.g., diarrhea), and otitis media. Her regular medications included Lanoxin and aspirin, with laxatives administered as needed. Intermittent episodes of apnea were also reported, which were alleviated by positioning the patient in the knee-chest posture. A complete corrective cardiac surgery is planned, pending stabilization of her overall physical condition.

Regarding her dental history, the patient's first dental visit occurred at 8 months of age, prior to cheiloplasty. At the second visit, although dental caries was detected, only topical fluoride treatment was provided. Bottle feeding continued until 3 years and 8 months of age, after her second palatoplasty. Currently, the patient frequently consumes drinking yogurt throughout the day as a substitute for milk.

Physical examination

The patient had a very small stature. Her weight (9.2 kg) and height (85.5 cm) were both below the 3rd percentile for her age. Her heart rate (105 beats per minute) and respiratory rate (22 breaths per minute) were within normal limits, and no adventitious breath sounds were noted. However, her blood pressure was low (80/50 mmHg) and oxygen saturation was 85-90%.

The patient exhibited global developmental delay, affecting cognitive skills, motor function, speech and language abilities, and social-emotional development. Her speech development was significantly delayed, with the ability to produce only a few isolated words and no complete sentences. The patient showed significant fearfulness, remained closely attached to her mother, and resisted contact with others. Her mother was also hesitant to enforce any activities or interventions, preferring not to pressure the patient.

The patient was noted to have microcephaly and characteristic craniofacial dysmorphism, including asymmetric crying facies, arched eyebrows, hypoplastic brow ridges, short palpebral fissures, telecanthus, a fleshy nose with a mildly deviated bulbous nasal tip and hypoplastic alae nasi, microstomia, and thin lips with scars from repaired bilateral cleft lip. Additional features included malar flatness and slightly posteriorly angulated low-set ears (Figure 1). Cyanosis was observed as bluish skin discoloration along with digital clubbing of both fingers (Figure 2A) and toes, in the absence of peripheral edema (Figure 2B). The abdomen was soft and non-tender, with no evidence of hepatomegaly.



Figure 1 Specific craniofacial dysmorphic features included asymmetric crying facies, arched eyebrows, hypoplastic brow ridges, short palpebral fissures, telecanthus, a fleshy nose with a mildly deviated bulbous nasal tip and hypoplastic alae nasi, microstomia, and thin lips with surgical scars from repaired cleft lip (B), as well as malar flatness and slightly posteriorly angulated low-set ears (A, C).



Figure 2 Clubbing of the fingers (A) and toes (B), accompanied by bluish skin discoloration.

Intraoral and radiographic findings

Intraoral examination revealed a repaired primary palate, with a remaining secondary cleft palate measuring approximately 10 mm in width and 20 mm in length. The patient exhibited poor oral hygiene, with generalized heavy plaque accumulation and moderate gingivitis. Congenital absence of the maxillary primary incisors and severe early childhood caries were noted. Due to the patient's uncooperative behavior, occlusion could not be assessed.

Multiple extensive carious lesions had destroyed the entire crowns of teeth 64, 71, 72, 73, 74, 81, 82, 83, and 84, leaving only retained roots. Pulpal involvement was identified in teeth 53, 55, 65, and 75, while caries extending to the dentin was observed in teeth 63 and 85 (Figure 3). A panoramic radiograph, obtained with difficulty, revealed a cleft palate along with congenital absence of the maxillary permanent incisors and all second premolars (Figure 4). Periapical radiographs taken under general anesthesia (GA) confirmed these findings and additionally demonstrated malformation of tooth 11 and agenesis of teeth 14, 24, and all second premolars (Figure 5).



Figure 3 Intraoral appearance showing generalized plaque accumulation and a large palatal fistula (A), along with multiple severely carious maxillary (A) and mandibular teeth (B).



Figure 4 Panoramic radiograph demonstrating multiple dental caries, congenital agenesis of several permanent teeth, and a visible cleft palate defect.

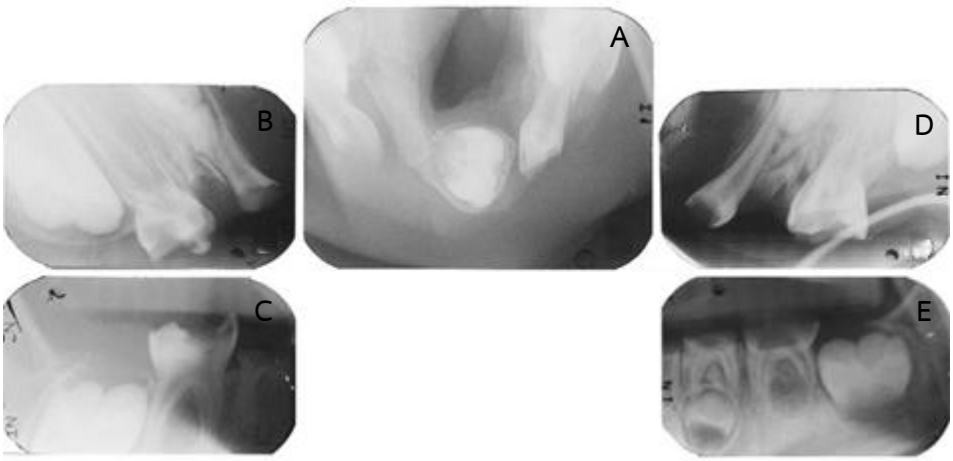

Figure 5 Periapical radiographs revealing a cleft palate, a malformed permanent maxillary incisor (A), multiple severely decayed teeth (A–E), and the congenital absence of several anterior and posterior permanent teeth (A–E).

Anesthetic and dental management

After multidisciplinary discussion among a pediatric dentist, pediatrician, anesthesiologist, and the patient's parents, full oral rehabilitation under GA was planned due to concerns over multiple antibiotic prophylaxis, the patient's uncooperativeness, and the risk of hypoxic spells.

One day prior to the operation, the patient was admitted to the pediatric ward of Srinagarind Hospital for preoperative evaluation. The full blood count and coagulation profiles were within normal limits. For endocarditis prophylaxis, the patient received 10 ml of oral amoxicillin (250 mg/5 ml) 30 minutes prior to surgery, as prescribed by the ward pediatrician.

General anesthesia was induced via sevoflurane inhalation, followed by endotracheal intubation. A moist throat pack was placed, and the patient was prepared and draped using standard sterile technique. Dental procedures included intraoral photography, full-mouth periapical radiographs, dental prophylaxis, and placement of stainless steel crowns on teeth 63 and 85. The maximum allowable dose of 2% mepivacaine with epinephrine 1:100,000 for this patient was calculated to be 40.48 mg (equivalent to 2.02 ml). However, only 1.8 ml was administered during the extraction of 13 severely decayed teeth, which were subsequently preserved for histological examination. Bleeding from the extraction sites—most of which were shallow—was adequately controlled with gauze pressure prior to throat pack removal. The patient was then extubated under the supervision of the anesthesiologist.

Postoperatively, the patient was closely monitored in the post-anesthesia care unit. Due to low oxygen saturation, full recovery of respiratory function and consciousness required approximately 4–5 hours. After recovery, the patient was transferred back to the ward. As prescribed by the pediatrician, postoperative medications included intravenous tranexamic acid (100 mg), Augmentin (300 mg) administered every 8 hours for 24 hours, and paracetamol syrup (120 mg) every 6 hours as needed. By that evening, the patient exhibited stable vital signs without fever, pain, or active bleeding, with only mild residual drowsiness.

Prior to discharge on the following day, the patient's mother was provided with comprehensive

home care instructions due to the child's extremely high risk of dental caries. These included mechanical plaque control, use of topical fluoride, and dietary counseling. The mother received hands-on training in brushing the patient's teeth using the scrub method with a pea-sized amount of fluoridated toothpaste (1,400–1,500 ppm) at least twice daily. Dietary counseling was provided to help avoid cariogenic foods, along with guidance to limit between-meal consumption of sugar-containing snacks or beverages to no more than 2–3 times per day. The importance of regular dental follow-up visits was also emphasized.

At the 3-month follow-up, the patient exhibited significant fear and anxiety. Due to persistent uncooperative behavior, protective stabilization by the mother was necessary to facilitate the clinical examination. All restorations remained intact; however, plaque accumulation was observed at the cervical margins of the stainless steel crowns, along with food debris in the oronasal fistula. The mother reported difficulty in brushing the patient's teeth due to behavior resistance and expressed concern about episodes of crying, which occasionally led to cyanosis. Despite these challenges, oral hygiene instructions and dietary advice were reinforced. The patient was scheduled for regular dental follow-up visits every 3 months.

According to dental histological analysis, ground sections of the extracted teeth could not be prepared as insufficient enamel remained due to the extensive crown destruction. However, decalcified sections of the left maxillary second primary molar, stained with hematoxylin and eosin, revealed normal findings (Figure 6).

In addition to dental issues, the patient continued to experience a combination of feeding difficulties, recurrent infections, and structural anomalies of the heart and palate, along with ongoing speech, learning, and developmental delays. These multifactorial challenges necessitated coordinated care from multiple medical and dental specialties. The mother acknowledged the complexity of the condition and reported that the patient had been placed on a timely, structured schedule of follow-up appointments with various specialists to ensure regular monitoring, evaluation, and management of the associated conditions.

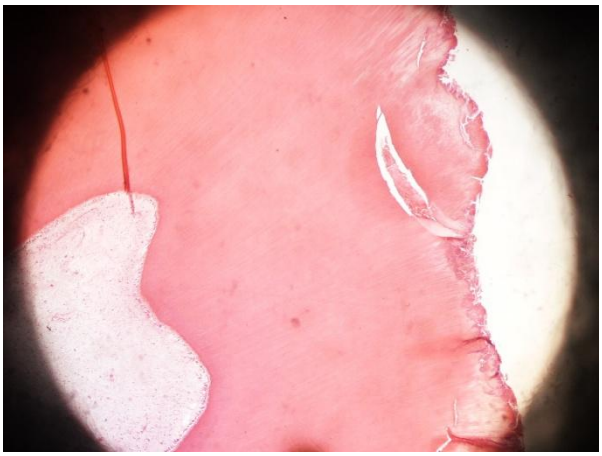

Figure 6 Hematoxylin and eosin-stained section of a primary maxillary second molar demonstrating a normal pulp–dentine complex.

Discussion

This patient exhibited hallmark features of 22q11.2 DS, including complex cyanotic congenital heart disease, craniofacial dysmorphism, bilateral complete cleft lip and palate, and anovestibular fistula. A history of multiple medical interventions and several acquired complications including prematurity, neonatal resuscitation, hypotonia, feeding and swallowing difficulties, hearing loss, hypernasal speech, global developmental delay, recurrent infections, and severe early childhood caries were also noted.

Compared to the general population, individuals with 22q11.2 DS face increased perioperative risks, including bleeding, atelectasis, seizures, and difficult intubation during general anesthesia.[7] Postoperative tachycardia following

multiple dental extractions in a 22q11.2 DS case has been reported.[17] Children with complex congenital heart disease undergoing non-cardiac surgery are at elevated risk of perioperative morbidity and mortality.[18] In this case, prolonged recovery after GA was likely due to low oxygen saturation. Appropriate-sized intubation equipment and meticulous perioperative and postoperative monitoring of ionized calcium, oxygen saturation, and heart rate are essential for such patients.[7]

Comprehensive dental management was successfully accomplished through collaboration among the family and multidisciplinary healthcare team. According to Bassett et al., dental evaluations in patients with 22q11.2 DS should begin between the ages of 1 and 5 years.[7] Despite early dental visits, this patient exhibited poor oral hygiene and severely decayed primary dentition. Several factors may have contributed to this outcome: enamel hypoplasia or hypomineralization—common in 22q11.2 DS—can elevate caries risk. Additionally, patients with this syndrome have been found to have reduced salivary flow and altered salivary composition, along with elevated levels of cariogenic bacteria.[19]

Feeding difficulties and limited caregiver ability to maintain oral hygiene due to the patient's complex medical conditions may have further exacerbated the situation. A high frequency of cariogenic food and medication intake, combined with inadequate oral hygiene, resulted in extensive caries and gingivitis. Moreover, children with congenital heart disease often exhibit higher caries prevalence and more untreated caries than their healthy peers.[20-21] Dental professionals must educate caregivers about the oral health implications and motivate them to maintain proper oral hygiene and regular dental care.

Although no histological abnormalities were observed in the primary teeth, this does not preclude future issues in the permanent dentition. Enamel hypomineralization is reported to occur more frequently in permanent than in primary teeth, and its occurrence is not always correlated with systemic health issues.[12] Future treatment planning should consider enamel defects, dental malformations and agenesis, cleft-related issues, caries, gingival disease, and malocclusion—necessitating multidisciplinary care.

Dental behavior management challenges and inadequate parental home care significantly limited the success of oral health management in this patient. The patient's inability to cooperate—resulting from global developmental delay in conjunction with complex cyanotic congenital heart disease and severe early childhood caries—necessitated treatment under general anesthesia, which did not lead to improved behavioral outcomes. Continued inadequacies in parental home care may further increase the risk of recurrent dental caries and periodontal disease, potentially necessitating repeated interventions under general anesthesia and negatively affecting the patient's systemic health.

Conclusion

Dental professionals must recognize that patients with 22q11.2 DS frequently present with complex systemic disorders, structural orofacial anomalies, and a high susceptibility to oral diseases. Preventive and therapeutic dental care should begin in early childhood and continue throughout life. Collaborative care involving specialists and supportive parental involvement is essential for achieving optimal oral health and overall well-being in affected individuals.

Acknowledgment

The authors are sincerely grateful to Mr. Chaiwut Kansin at the Faculty of Dentistry, Khon Kaen University for his assistance in photographic preparation.

Ethics

Before initiating treatment, the patient's parents were thoroughly informed about the treatment plan, procedures, potential risks, and expected benefits. They expressed their understanding and consented to proceed. The mother provided written informed consent for both the treatment and the use of the patient's records and photographs.

Conflict of Interest

The authors have no conflicts of interest to report.

Funding

None

References

1. McDonald-McGinn DM. 22q11.2 deletion syndrome: a tiny piece leading to a big picture. Am J Med Genet A. 2018;176(10):2055-7.
2. McDonald-McGinn DM, Sullivan KE, Marino B, Philip N, Swillen A, Vorstman JA, et al. 22q11.2 deletion syndrome. Nat Rev Dis Primers. 2015;1:15071.
3. Swillen A, Vogels A, Deveriendt K, Fryns JP. Chromosome 22q11 deletion syndrome: update and review of the clinical features, cognitive-behavioral spectrum, and psychiatric complications. Semin Med Genet. 2000;97(2):128-35.
4. McDonald-McGinn DM, Kirchner RE, Goldmuntz E, Sullivan K, Eicher P, Gerdes M, et al. The Philadelphia story: the 22q11.2 deletion: report on 250 patients. Genet Couns. 1999;10(1):11-24.
5. McDonald-McGinn DM, Hain HS, Emanuel BS, Zackai EH. 22q11.2 Deletion Syndrome. 1999 Sep 23 [Updated 2025 May 8]. In: Adam MP, Feldman J, Mirzaa GM, et al., editors. GeneReviews® [Internet]. Seattle (WA): University of Washington, Seattle; 1993-2025. Available from: https://www.ncbi.nlm.nih.gov/books/NBK1523/
6. O'Connor C. Fluorescence in situ hybridization (FISH). Nat Educ. 2008;1(1):171.
7. Bassett AS, McDonald-McGinn DM, Devriendt K, Digilio MC, Goldenberg P, Habel A, et al. Practical guidelines for managing patients with 22q11.2 deletion syndrome. J Pediatr. 2011;159(2):332-9.
8. Klinberg G, Oskarsdóttir S, Johannesson EL, Norén JG. Oral manifestations in 22q11 deletion syndrome. Int J Paediatr Dent. 2002;12(1):14-23.
9. Batzir NA, Shohat M, Maya I. Chromosomal microarray analysis (CMA) a clinical diagnostic tool in the prenatal and postnatal settings. Pediatr Endocrinol Rev. 2015;13(1):448-54.
10. Schouten JP, McElgunn CJ, Waaijer R, Zwijnenburg D, Diepvens F, Pals G. Relative quantification of 40 nucleic acid sequences by multiplex ligation-dependent probe amplification. Nucleic Acids Res. 2002;30(12):e57.
11. Heliövaara A, Rantanen I, Arte S. Dental development and tooth agenesis in children with velocardiofacial syndrome. Int J Paediatr Dent. 2011;21(6):446-50.
12. Nordgarden H, Lima K, Skogedal N, Folling I, Storhaug K, Abrahamsen TG, et al. Dental developmental disturbances in 50 individuals with the 22q11.2 deletion syndrome; relation to medical conditions? Acta Odontol Scand. 2012;70(3):194-201.
13. Lewyllie A, Roosenboom J, Indencleef K, Claes P, Swillen A, Devriendt K, et al. A comprehensive craniofacial study of 22q11.2 deletion syndrome. J Dent Res. 2017;96(12):1386-91.
14. Klingberg G, Dietz W, Oskarsdóttir S, Odelius H, Gelander L, Norén JG. Morphological appearance and chemical composition of enamel in primary teeth from patients with 22q11 deletion syndrome. Eur J Oral Sci. 2005;113(4):303-11.
15. Fukui N, Amano A, Akiyama S, Daikoku H, Wakisaka S, Morisaki I. Oral findings in DiGeorge syndrome: clinical features and histologic study of primary teeth. Oral Surg Oral Med Oral Pathol Oral Radiol Endod. 2000;89(2):208-15.

16. Wong DH, Rajan S, Hallett KB, Manton DJ. Medical and dental characteristics of children with chromosome 22q11.2 deletion syndrome at the Royal Children's Hospital, Melbourne. Int J Paediatr Dent. 2021;31(6):682-90.
17. Passariello M, Perkins R. Unexpected postoperative tachycardia in a patient with 22q11 deletion syndrome after multiple dental extractions. Paediatr Anaesth. 2005;15(12):1145-6.
18. White MC, Peyton JM. Anaesthetic management of children with congenital heart disease for non-cardiac surgery. Contin Educ Anaesth Crit Care Pain. 2012;12(1):17-22.
19. Klingberg G, Lingström P, Oskarsdóttir S, Friman V, Bohman E, Carlén A. Caries-related saliva properties in individuals with 22q11 deletion syndrome. Oral Surg Oral Med Oral Pathol Oral Radiol Endod. 2007;103(4):497-504.
20. da Fonseca MA, Evans M, Teske D, Thikkurissy S, Amini H. The impact of oral health on the quality of life of young patients with congenital cardiac disease. Cardiol Young. 2009;19(3):252-6.
21. Stecksén-Blicks C, Rydberg A, Nyman L, Asplund S, Svanberg C. Dental caries experience in children with congenital heart disease: a case-control study. Int J Paediatr Dent. 2004;14(2):94-100.

Corresponding author:

Jinda Lertsirivorakul
Faculty of Dentistry, Bangkokthonburi University, Bangkok 10170
Tel. : +66 2 800 6800 #2013
E-mail : jinda.ler@bkkthon.ac.th

KDJ
Khon Kaen University
Dental Journal

ลักษณะทางคลินิกและการจัดการทางทันตกรรมในผู้ป่วยเด็กที่เป็นกลุ่มอาการการขาดหายของแขนข้างยาวของโครโมโซม 22 ที่ตำแหน่ง 11.2: รายงานผู้ป่วย

จินดา เลิศศิริวรกุล [1,] ดวงหทัย เอี่ยมวิถีวนิช [2] กุณฑล วิชาจารย์ [3] อชิรวุธ สุพรรณเภสัช [4]*

รายงานผู้ป่วย

บทคัดย่อ

วัตถุประสงค์: รายงานนี้มีจุดประสงค์เพื่อบรรยายลักษณะของช่องปากใบหน้าและฟัน ตลอดจนการจัดการทางทันตกรรมพร้อมมูลภายใต้การดมยาสลบในเด็กคนหนึ่งที่ได้รับการวินิจฉัยเป็น 22q11.2 DS

รายงานผู้ป่วย: เด็กอายุ 4 ปีมาพบแพทย์ด้วยความผิดปกติแต่กำเนิดหลายชนิด รวมถึงโรคหัวใจพิการ แต่กำเนิดชนิดเขียวที่ซับซ้อน ความผิดปกติของกะโหลกศีรษะและใบหน้า ภาวะปากแหว่งเพดานโหว่งชนิดสมบูรณ์ทั้งสองข้าง และมีรูทวารแฝงในช่องคลอด ผู้ป่วยยังมีภาวะกล้ามเนื้ออ่อนแรง ปัญหาการให้อาหารและการกลืน สูญเสียการได้ยิน พูดเสียงขึ้นจมูกเกินปกติ และมีพัฒนาการโดยรวมล่าช้า ผู้ป่วยเคยได้รับการผ่าตัดใหญ่หลายครั้ง อันเป็นส่วนหนึ่งของการดูแลแบบสหสาขาวิชาชีพ การตรวจทางคลินิกและภาพรังสีพบฟันผุจำนวนมากจัดเป็นโรคฟันผุปฐมวัยขั้นรุนแรง ตลอดจนความผิดปกติของรูปร่างฟันและภาวะฟันหายของฟันแท้ที่กำลังสร้างหลายซี่ เนื่องจากผู้ป่วยมีความสามารถในการร่วมมือจำกัด มีโรคร่วมทางการแพทย์ที่สำคัญ และต้องการการรักษาทางทันตกรรมอย่างกว้างขวาง จึงได้รับการรักษาทันตกรรมพร้อมมูลภายใต้การดมยาสลบ ซึ่งดำเนินการสำเร็จลุล่วง แม้ว่าการฟื้นตัวหลังผ่าตัดจะใช้เวลานาน ผู้ป่วยได้รับการนัดหมายเพื่อติดตามด้านทันตกรรมและการแพทย์อย่างสม่ำเสมอ เพื่อให้การดูแลป้องกัน การเฝ้าติดตาม และการจัดการในระยะยาวอย่างต่อเนื่อง

บทสรุป: ผู้ป่วย 22q11.2 DS มักจะมีปัญหาทางการแพทย์มากมายแฝงอยู่ และมีความเสี่ยงสูงต่อความผิดปกติของช่องปากและใบหน้า รวมถึงโรคช่องปากต่าง ๆ การดูแลทางทันตกรรมควรเริ่มตั้งแต่วัยเยาว์และดำเนินต่อไปตลอดชีวิตของผู้ป่วย การจัดการที่ประสบความสำเร็จต้องการการทำงานร่วมกันระหว่างแพทย์และทันตแพทย์เฉพาะทางโดยการสนับสนุนจากผู้ดูแลที่มีข้อมูลและส่วนร่วม เพื่อให้ได้สุขภาพช่องปากที่เหมาะสมที่สุดและยกระดับคุณภาพชีวิตโดยรวมของผู้ป่วยเหล่านี้

คำไขรหัส: กลุ่มอาการการขาดหายของแขนข้างยาวของโครโมโซม 22 ที่ตำแหน่ง 11.2/ กลุ่มอาการดิจอร์จ/ กลุ่มอาการเวโลคาร์ดิโอเฟเชียล/ เพดานโหว่/ เตตราโลจีออฟฟาลโลต์

ผู้ประพันธ์บรรณกิจ

จินดา เลิศศิริวรกุล
คณะทันตแพทยศาสตร์ มหาวิทยาลัยกรุงเทพธนบุรี
กรุงเทพฯ 10170
โทรศัพท์ : 02 800 6800 #2013
จดหมายอิเล็กทรอนิกส์ : jinda.ler@bkkthon.ac.th

[1] คณะทันตแพทยศาสตร์ มหาวิทยาลัยกรุงเทพธนบุรี
[2] แผนกทันตกรรม โรงพยาบาลบ้านฉาง จังหวัดระยอง
[3] หน่วยเวชพันธุศาสตร์ ภาควิชากุมารเวชศาสตร์ คณะแพทยศาสตร์ มหาวิทยาลัยขอนแก่น
[4] สาขาวิชาชีวเวชศาสตร์ช่องปาก คณะทันตแพทยศาสตร์ มหาวิทยาลัยขอนแก่น
[*] ผู้ประพันธ์บรรณกิจ