

# Cytomegalovirus retinitis and telemedicine

**Sakarin Ausayakhun, M.D. and Somsanguan Ausayakhun, M.D., MH.Sc.**

Department of Ophthalmology, Faculty of Medicine, Chiang Mai University

---

**Abstract** The most common ocular opportunistic infection in AIDS patients is cytomegalovirus (CMV) retinitis, which is characterized by dense retinal whitening and hemorrhage. An experienced ophthalmologist can detect CMV retinitis by looking through a dilated pupil in a highly sensitive and specific manner. This indirect ophthalmoscopy technique does not need expensive equipment, but it does require a high level of expertise and time consumption from ophthalmologists. However, telemedicine can enhance the ability of general practitioners in providing CMV retinitis care, and it is possibly the most reliable method for improving screening of this blinding disease. Telemedicine could be used in the future for screening CMV retinitis, and providing a forum for both monitoring quality control and mentoring trainee non- ophthalmologists. **Chiang Mai Medical Journal 2012;51(4):131-135.**

---

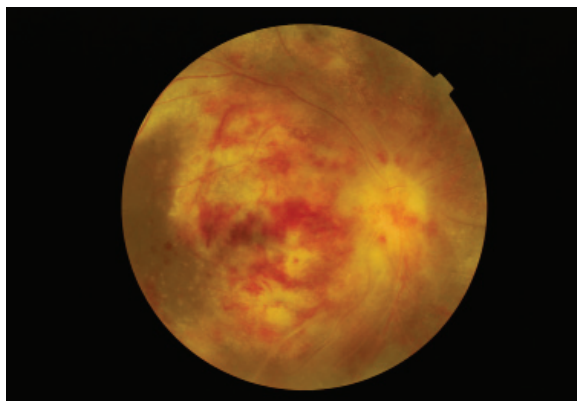
**Keywords:** Cytomegalovirus retinitis, blindness, HIV, AIDS, telemedicine

Cytomegalovirus (CMV) retinitis is an inflammatory disorder of the eye, which can lead to permanent and complete blindness if left untreated. CMV is a member of the herpes virus family, and like other viruses in this class, its infection leads to a permanent carrier state. It is a ubiquitous infection, from which an estimated 50-90% of individuals are infected by adulthood [1]. However, it does not cause disease in immunocompetent hosts, who recover from a mild viral illness occurring immediately after infection. In contrast, CMV re-activation may occur in severely immunocompromised patients, such as those with advanced AIDS or immunosuppressant administration after organ transplantation. Not only the eye may be affected in these patients, but also the entire nervous system, and

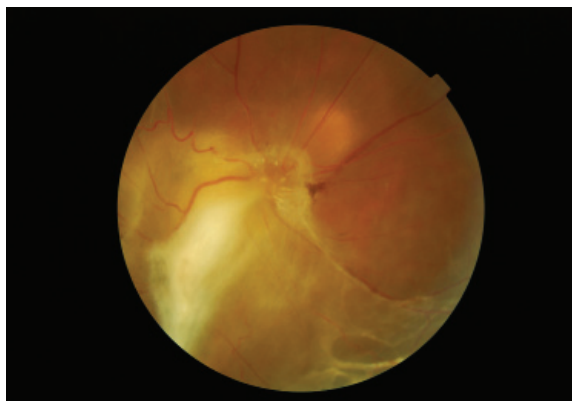
CMV can lead to blindness, paralysis and death [2]. The initial sign of active systemic CMV infection is often CMV retinitis, which can be observed as characteristic changes in the appearance of the retina [2-4]. If patients with active CMV can be identified in a systematic and efficient manner, initiation of anti-viral treatment can reduce rates of blindness, neurological deficits, and mortality significantly.

## Characteristics of CMV Retinitis

CMV retinitis is typified by whitening and hemorrhage of the retina, which spread centrifugally in a “brush-fire” pattern [3] (Figure 1). If untreated, CMV retinitis slowly advances, and blindness results from optic nerve or macula



**Figure 1.** “Brush-fire” pattern CMV retinitis. Figure 2. Retinal detachment in CMV retinitis.



**Figure 2.** Retinal detachment in CMV retinitis.

involvement, or retinal detachment [5-6] (Figure 2). Most Southeast Asian and African patients with CMV retinitis are treated with intravitreal ganciclovir injections until antiretroviral therapy results in immune reconstitution [7-11].

### The emerging epidemic of CMV retinitis

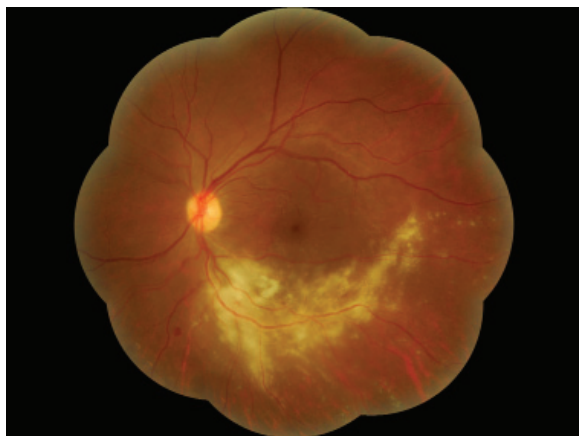
UNAIDS estimates that 34.2 million people are infected with HIV worldwide, with Sub-Saharan Africa and Southeast Asia sharing the highest burden, of which Thailand has 1.3% prevalence [12]. Many HIV patients in these countries are at risk of CMV retinitis. These authors recently reported 33% prevalence of CMV retinitis in newly diagnosed HIV patients in northern Thailand [13]. In addition, CMV retinitis was the second most common cause of blindness seen at Chiang Mai University Hospital, accounting for 19% of all bilateral blindness cases [14]. However, CMV retinitis often goes undiagnosed and untreated, due to an inadequate number of ophthalmologists. Routine screening of AIDS patients for CMV retinitis simply does not occur. Most patients are referred to ophthalmologists only after experiencing marked visual symptoms, at which point irreversible retinal damage has occurred already.

### Diagnosis of CMV retinitis

By using a binocular indirect ophthalmoscope and condensing lens to look through a dilated pupil, an experienced ophthalmologist can detect CMV retinitis in a highly sensitive and specific manner. This indirect ophthalmoscopy technique does not need expensive equipment, but it does require a high level of expertise and time consumption from ophthalmologists. As the number of at-risk patients is large; and consistently increasing in regions affected by the current HIV/AIDS pandemic, a novel solution utilizing non-ophthalmologists must be developed, in order to increase the CMV retinitis screening capabilities of local health care teams.

### Strategies for improving access to screening for CMV retinitis

Two potential methods that would involve non-ophthalmologists in diagnosing CMV retinitis include (1) the use of indirect ophthalmoscopy in training non-ophthalmologists to diagnose CMV retinitis, and (2) train non-ophthalmologists to obtain retinal images that can be evaluated by telemedicine. Retinal photography, while currently expensive, is not technically challenging, and is likely to be more reliable than a non-ophthalmologist's clinical exam.



**Figure 3.** A mosaic image with the Topcon TRC-NW 6S.

### Telemedicine in developing countries

Telemedicine uses communication networks for delivering health care services [15]. It has been used also for diabetic retinopathy, and retinopathy of prematurity screening [16-20], in which non-specialists capture retinal images and transmit them to a reading center for diagnosis, thus prompting referral for a clinically significant disease. The use of this model, and results from some previous studies have shown that infection usually involves zone 1 or 2 [3, 21]. CMV retinitis would be an ideal candidate for telemedicine; as its retinal changes are photographed easily with a photographic grading system that is established already [22], and early treatment is effective.

### Telemedicine for CMV retinitis

Telemedicine could provide an effective screening mechanism in many developing countries that have a high burden of HIV/AIDS and an insufficient number of ophthalmologists. Early diagnosis and treatment can prevent blindness, which is especially important in this era of enhanced access to highly active antiretroviral therapy (HAART), and enable longer survival rates in persons with AIDS. A telemedicine-screening programme for CMV retinitis was validated in Singapore, using indirect ophthalmosco-

py as the gold standard. In this study, the dilated retinal photography with 9 fields of 50 degrees was 100% sensitive and 99.8% specific [23].

### Telemedicine and CMV retinitis at Chiang Mai University Hospital

A digital retinal camera was used in a cross-sectional study at Chiang Mai University Hospital to determine the utility of remote assessment of retinal photographs (i.e., telemedicine) as a screening test for CMV retinitis. Ninety four consecutive patients were screened in this study with the Topcon TRC-NW 6S, taking 9 overlapping 45-degree fundus photographs that were converted automatically into an 85-degree mosaic image (Figure 3). Three remote graders assessed each mosaic image for the presence of CMV retinitis. All patients also were examined by an attending gold standard ophthalmologist for the presence of CMV retinitis. Telemedicine was found to be a promising screening strategy for CMV retinitis, with sensitivity ranging from 89 to 91% and specificity from 85 to 88% [21]. In an ancillary study, 3 auto-mosaic programs were used to create mosaic images of the retinal photographs taken during the study. The i2k Retina software package was found to be superior to 2 other products in terms of minimizing mosaic stitching errors [24]. In northern Thailand, patients with CMV retinitis presented with advanced disease. The clinical features of 52 patients were assessed, with newly diagnosed CMV retinitis as part of the telemedicine study, and a high proportion of patients was found with bilateral CMV retinitis (46%), as well as unilateral and bilateral blindness (27% and 8%, respectively). Eyes with CMV retinitis frequently had retinitis affecting the fovea (22%) or optic nerve (23%), and retinitis lesions were generally large, with 58% of the eyes having lesions greater than 25% of the retinal surface area [25]. It was hypothesized that the advanced nature of CMV retinitis most likely came from delayed diagnosis. However, this study had several limitations, of which one was it being conducted at a tertiary medical center that may limit generalization of

the results. Other limitations were failure of the imaging system to capture images of the peripheral retina, specifically zone 3 and outer zone 2, and poor image quality from inadequate papillary dilatation and opacity of the ocular media.

## Conclusion and Future Directions

To address the lack of human resources, there should be a shift of paradigm for eye examination from only the area of the ophthalmologist. All medical personnel could be trained to use fundus cameras for detecting cases that require an ophthalmologist review. Recently, an ultra-wide fundus photography system was used to image CMV retinitis [26], and it captured greater areas of total retina and peripheral lesions. This camera is more expensive than a standard fundus camera, and may be not affordable in many developing countries.

However, there are less expensive cameras being developed [27], and enhanced broadband capabilities are becoming available over cell phone lines. In the near future, CMV retinitis screening by telemedicine will be an option even in remote areas without high speed internet. High quality, low cost, portable digital imaging equipment should be developed in resource-limited settings.

## References

1. **Wiegand TW, Young LH.** Cytomegalovirus retinitis. *Int Ophthalmol Clin* 2006;46:91-110.
2. **Whitley RJ, Jacobson MA, Friedberg DN, et al.** Guidelines for the treatment of cytomegalovirus diseases in patients with AIDS in the era of potent antiretroviral therapy: recommendations of an international panel. *International AIDS Society-USA. Arch Intern Med* 1998;158:957-69.
3. **Holland GN, Vaudaux JD, Jeng SM, et al.** Characteristics of untreated AIDS-related cytomegalovirus retinitis. I. Findings before the era of highly active antiretroviral therapy (1988 to 1994). *Am J Ophthalmol* 2008; 145:5-11.
4. **Holland GN, Vaudaux JD, Jeng SM, et al.** Characteristics of untreated AIDS-related cytomegalovirus retinitis. II. Findings in the era of highly active antiretroviral therapy (1997 to 2000). *Am J Ophthalmol* 2008; 145:12-22.
5. **Tangmonkongvoragul C, Ausayakhun S.** Causes of visual acuity loss among HIV-infected patients with cytomegalovirus retinitis in the era of highly active antiretroviral therapy in Chiang Mai university hospital. *J Med Assoc Thai* 2012;95(Suppl 4):S129-35.
6. **Holbrook JT, Jabs DA, Weinberg DV, et al.** Visual loss in patients with cytomegalovirus retinitis and acquired immunodeficiency syndrome before widespread availability of highly active antiretroviral therapy. *Arch Ophthalmol* 2003;121:99-107.
7. **Heiden D, Ford N, Wilson D, et al.** Cytomegalovirus retinitis: the neglected disease of the AIDS pandemic. *PLoS Med* 2007;4:e334.
8. **Heinemann MH.** Long-term intravitreal ganciclovir therapy for cytomegalovirus retinopathy. *Arch Ophthalmol* 1989;107:1767-72.
9. **Ausayakhun S, Yuvaves P, Ngamtiphakom S, Prasitsilp J.** Treatment of cytomegalovirus retinitis in AIDS patients with intravitreal ganciclovir. *J Med Assoc Thai* 2005;88(Suppl 9):S15-20.
10. **Yutthitham K, Ruamviboonsuk P.** The high-dose, alternate-week intravitreal ganciclovir injections for cytomegalovirus retinitis in acquired immune deficiency syndrome patients on highly active antiretroviral therapy. *J Med Assoc Thai* 2005;88(Suppl)9:S63-8.
11. **Teoh SC, Ou X, Lim TH.** Intravitreal ganciclovir maintenance injection for cytomegalovirus retinitis: efficacy of a low-volume, intermediate-dose regimen. *Ophthalmology* 2012;119:588-95.
12. **AIDS epidemic update-The latest epidemiology data.** Available at: <http://www.unaids.org/en/dataanalysis/datatools/aidsinfo/>. Accessed October 10, 2012.
13. **Ausayakhun S, Watananikorn S, Ittipunkul N, Chaidaroon W, Patikulsila P, Patikulsila D.** Epidemiology of the ocular complications of HIV infection in Chiang Mai. *J Med Assoc Thai* 2003;86:399-406.
14. **Pathanapitoon K, Ausayakhun S, Kunavisarut P, et al.** Blindness and low vision in a tertiary ophthalmologic center in Thailand: the importance of cytomegalovirus retinitis. *Retina* 2007;27:635-40.
15. **Sood S, Mbarika V, Jugoo S, et al.** What is telemedicine? A collection of 104 peer-reviewed perspectives and theoretical underpinnings. *Telemed J E Health* 2007;13:573-90.
16. **Lin DY, Blumenkranz MS, Brothers RJ, Grosvenor DM.** The sensitivity and specificity of single-field non-mydiatic monochromatic digital fundus photography with remote image interpretation for diabetic retinopathy screening: a comparison with ophthalmoscopy and standardized mydiatic color photography. *Am J Ophthalmol* 2002;134:204-13.
17. **Ruamviboonsuk P, Wongcumchang N, Surawongsin P, et al.** Screening for diabetic retinopathy in rural area using single field, digital fundus images. *J Med*

- Assoc Thai 2005;88:176-80.
18. **Ruamviboonsuk P, Teerasuwanajak K, Tiensuwan M, et al.** Interobserver agreement in the interpretation of single-field digital fundus images for diabetic retinopathy screening. *Ophthalmology* 2006;113:826-32.
  19. **Chiang MF, Keenan JD, Starren J, et al.** Accuracy and reliability of remote retinopathy of prematurity diagnosis. *Arch Ophthalmol* 2006;124:322-7.
  20. **Jackson KM, Scott KE, Graff Zivin J, et al.** Cost-utility analysis of telemedicine and ophthalmoscopy for retinopathy of prematurity management. *Arch Ophthalmol* 2008;126:493-9.
  21. **Ausayakhun S, Skalet AH, Jirawison C, et al.** Accuracy and reliability of telemedicine for diagnosis of cytomegalovirus retinitis. *Am J Ophthalmol* 2011;152:1053-8 e1.
  22. **Holland GN, Buhles WCJ, Mastre B, Kaplan HJ.** A controlled retrospective study of ganciclovir treatment for cytomegalovirus retinopathy: use of a standardized system for the assessment of disease outcome. *Arch Ophthalmol* 1989;107:1759-66.
  23. **Leo S-W.** Telemedicine screening for cytomegalovirus retinitis using digital photography; Poster 10. American Academy of Ophthalmology Annual Meeting. Anaheim, California; 2003.
  24. **Chen J, Ausayakhun S, Jirawison C, et al.** Comparison of autophotomontage software programs in eyes with CMV retinitis. *Invest Ophthalmol Vis Sci* 2011;52:9339-44.
  25. **Ausayakhun S, Keenan JD, Jirawison C, et al.** Clinical Features of Newly Diagnosed Cytomegalovirus Retinitis in Northern Thailand. *Am J Ophthalmol* 2012;153:923-31.
  26. **Mudvari SS, Virasch VV, Singa RM, MacCumber MW.** Ultra-wide-field imaging for cytomegalovirus retinitis. *Ophthalmic Surg Lasers Imaging* 2010;41: 311-5.
  27. **Constable IJ, Yogesana K, Eikelboom R, Barry C, Cuypers M.** Fred Hollows lecture: digital screening for eye disease. *Clin Experiment Ophthalmol* 2000;28: 129-32.

### จดตาอักเสบจากไซโตเมกกาโลไวรัสและการแพทย์ทางไกล

ศักรินทร์ อัญญคุณ, พ.บ., สมสงวน อัญญคุณ, พ.บ.  
ภาควิชาจักษุวิทยา คณะแพทยศาสตร์ มหาวิทยาลัยเชียงใหม่

#### บทคัดย่อ

จดตาอักเสบจากไซโตเมกกาโลไวรัสเป็นภาวะติดเชื้อฉวยโอกาสทางตาที่พบบ่อยที่สุดในผู้ป่วยเอดส์ ลักษณะของจดตาที่อักเสบจะเป็นแผ่นหนาขาวและเลือดออก การวินิจฉัยโดยจักษุแพทย์ทำได้โดยตรวจจดตามือขยายม่านตาแล้วด้วยเครื่องตรวจจดตาแบบอ้อม ซึ่งให้ความไวและความจำเพาะสูง การตรวจวิธีนี้ไม่ต้องใช้เครื่องมือราคาแพง แต่ผู้ตรวจต้องมีความชำนาญและใช้เวลาในการฝึกฝน การใช้การแพทย์ทางไกลจะช่วยเพิ่มความสามารถของแพทย์ทั่วไปในการดูแลผู้ป่วยจดตาอักเสบจากไซโตเมกกาโลไวรัส และอาจเป็นวิธีที่ช่วยการคัดกรองภาวะตาบอดจากโรคนี้ที่เชื่อถือได้ที่สุด ในอนาคตการแพทย์ทางไกลอาจใช้สำหรับการตรวจคัดกรองโรคจดตาอักเสบจากไซโตเมกกาโลไวรัส และดูแลผู้ป่วยเหล่านี้สำหรับผู้ที่ไม่มีไข้จักษุแพทย์ เชียงใหม่เวชสาร 2555;51(4):131-135.

**คำสำคัญ:** Cytomegalovirus (CMV) retinitis, blindness, HIV, AIDS, telemedicine, retinal photography