

Subcutaneous entomophthoramycosis in a healthy 9-year-old boy

Peninnah Oberdorfer, M.D.,¹ Piti Phloenchaiwanit, M.D.,² Kritsana Kongthavon-sakul, M.D.,¹ Benjaporn Chaiwun, M.D.³

¹Department of Pediatrics, Faculty of Medicine, Chiang Mai University, ²Department of Pediatrics, Chiang Rai Regional Hospital, Chiang Rai, ³Department of Pathology, Faculty of Medicine, Chiang Mai University

Abstract

Pediatric entomophthoramycosis is an uncommon disease. We reported a case of a healthy 9-year-old boy with a subcutaneous mass under his right eyebrow. The mass was 2 x 1 cm in size and had no signs of inflammation. The patient had neither previous underlying diseases nor trauma. A histopathologic examination of the mass revealed eosinophilic granulomas and broad ribbon like hyphae, which are characteristic of entomophthoramycosis. After 6-weeks treatment with trimethoprim-sulfamethoxazole and itraconazole, the soft tissue mass decreased in size and disappeared. **Chiang Mai Medical Journal 2012;51(4):125-129.**

Keywords: Entomophthoramycosis, fungal infection

Background

Entomophthoramycosis is an uncommon infectious disease in children. According to estimates, about 500 cases occur in the United States annually [1]. It is caused by a fungus in the subphylum Entomophthoromycotina, class Zygomycetes. This class includes Mucormycotina and Entomophthoromycotina [2], with both types appearing typically as broad (5 to 15 µm in diameter), ribbon-like, thin walled, irregularly branched, and mostly aseptate hyphae [3]. They are common in the environment and can be found in the soil. They produce spores that can cause infection in humans when inhaled or

through direct skin inoculation. Entomophthoramycosis most likely occurs in patients who are immunocompetent, whereas mucormycosis mostly occurs in those that are immunocompromised [4]. There are few case reports in Thailand about entomophthoramycosis in adults and children [5-8]. Over a 15-year period, Ramathibodi University Hospital in Bangkok reported only 5 cases among adults aged 20 to 65 years in a recent case series and review of pathological findings [7]. Among studies in children, only 8 cases have been reported in the past decade [5-8]. This study presents the first pediatric case reported in Chiang Mai University Hospital (CMUH).

Case presentation

History

A 9-year-old healthy Thai boy was transferred to the Paediatric Outpatient Department of CMUH with a 2-month history of a slow-growing lump under his right eyebrow. He reported no pain, redness, or warmth at the lump. He did not have fever, weight loss or loss of appetite. He stated that his vision was normal and he could move his eyes without pain. There was no history of recent trauma or exposure to animals. He had completed immunizations according to Thai guidelines and had normal growth and development. He reported having no underlying diseases. One month before admission to CMUH, a private hospital diagnosed him as having an abscess at his right eyebrow, and he was treated with 3-days of intravenous cloxacillin without improvement. An incisional biopsy was performed, and the histopathology report showed fibro-fatty tissue with heavy infiltration of chronic inflammatory cells, which were predominantly eosinophils. The mass persisted without signs of inflammation and an excisional biopsy was performed at the private hospital 2 weeks before referral to CMUH. Tissue cultures and polymerase chain reaction (PCR) test were not carried out.

Two weeks after the excisional biopsy, the remaining mass (size: 2 x 1 cm) under the patient's right eyebrow had an overlying scar. The mass had a rubbery consistency, which was movable and without signs of inflammation (Figure 1A). The remaining findings of the patient's physical examination were unremarkable.

Laboratory studies showed a white blood cell count of 6,860/mm³ (66% neutrophils, 20% lymphocytes, 7% monocytes, 5% eosinophils, 1% basophils, and 1% atypical lymphocytes). The patient's hemoglobin level was 13 g/dL, hematocrit level 39%, and platelet count 227 x 10³/

mm³. Hemocultures were negative for bacteria or fungi. Ultrasonography of the mass revealed a subcutaneous, heterogeneous, echoic mass of about 2 cm in diameter (Figure 2A) at the right side of the forehead without extension to the cranial vault. The histopathology from the first incisional biopsy specimens revealed fibro-fatty tissue with heavy infiltration of chronic inflammatory cells, which were predominantly eosinophils with some lymphocytes and epithelioid histiocytes. The histopathology from the second specimens showed heavy infiltration of inflammatory cells among fibrous stroma and bundles of muscle fibres (Figure 3A); multiple small granulomas consisting of epithelioid histiocytes and multinucleated giant cells (Figure 3B); Charcot-Leyden crystals (Figure 3C); and broad, ribbon-like fungal hyphae (Figure 3D), which were compatible with Zygomycosis.

The final diagnosis was Entomophthoramycosis under the right eyebrow.

The patient was treated for 6 weeks with trimethoprim-sulfamethoxazole (8 mg/kg/day of trimethoprim) and itraconazole (7 mg/kg/day). The mass regressed within 2 weeks and completely disappeared within 6 weeks (Figure 1B, 2B). No complications occurred, and there was no recurrence after 6-months of treatment.

Discussion

Entomophthoramycosis in immunocompetent and immunocompromised hosts is reported as a rare disease worldwide, including Thailand [5-13]. It is caused by fungal infection in the order of Mucormycotina and Entomophthoromycotina [2]. Entomophthorales, which occur predominantly in immunocompetent patients,

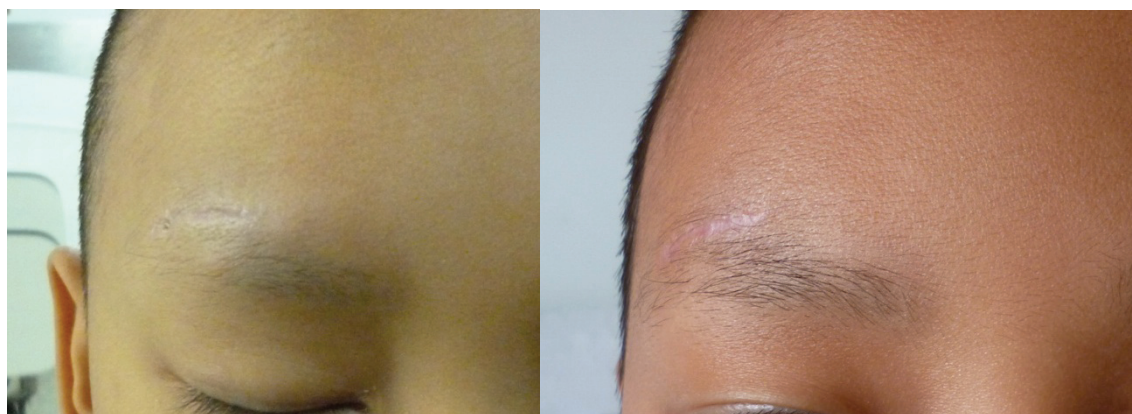

Figure 1. A (left): Subcutaneous mass under the right eyebrow with overlying excisional scar from a biopsy. B (right): After 6-weeks treatment.

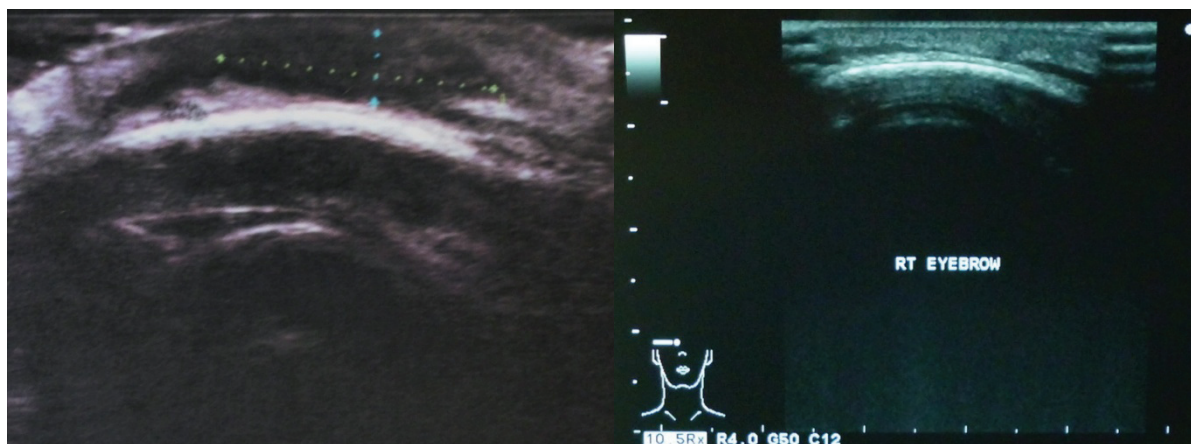

Figure 2. **A** (left): Subcutaneous heterogeneous echoic mass, 12.2 x 17.7 x 4.4 mm., **B** (right): After 6-weeks treatment, no evidence of a subcutaneous echoic mass.

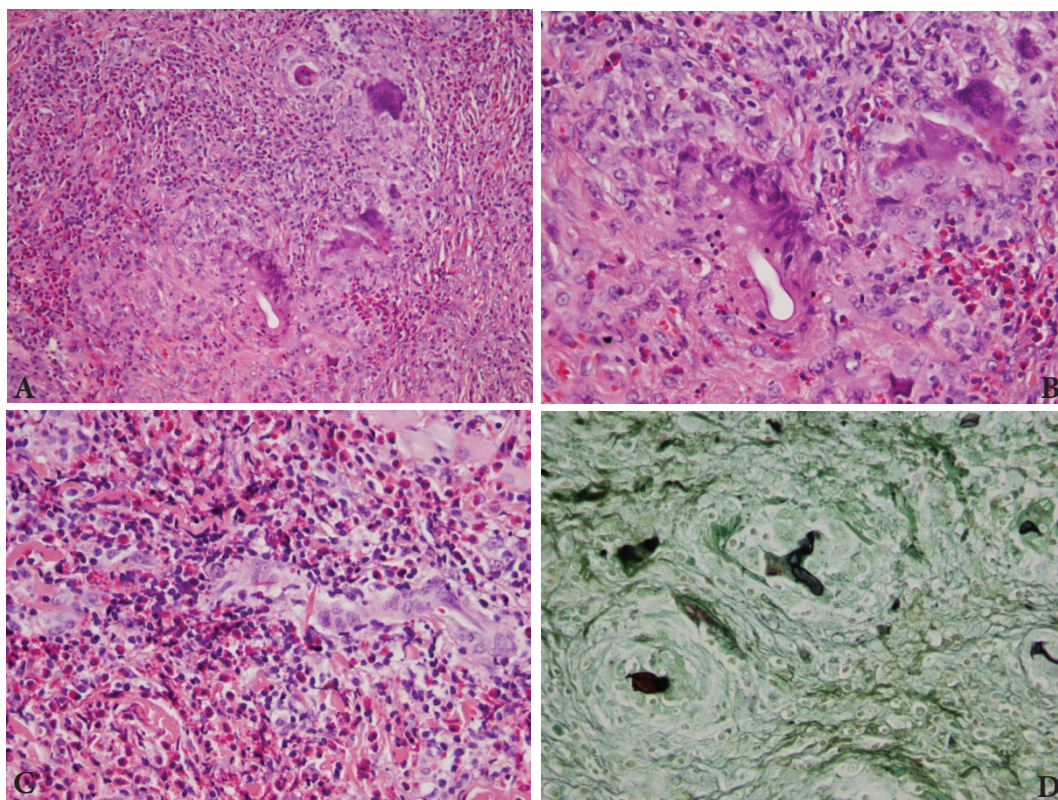


Figure 3. **A** (upper left): H&E stain (200X)., **B** (upper right): H&E stain (400X): Sections showing heavy infiltration of inflammatory cells among fibrous stroma and bundles of muscle fibres. The inflammatory cells are predominantly lymphocytes and eosinophils, with multiple small granulomas consisting of epithelioid histiocytes and multinucleated giant cells. Broad hyphae in multinucleated giant cells also are present (arrow)., **C** (lower left): H&E stain (400X): Charcot-Leyden crystals (arrow)., **D** (lower right): GMS stain (400X): Broad, ribbon-like fungal hyphae (arrow).

are divided into two genera, *Conidiobolus* and *Basidiobolus* [4]. *Conidiobolus* usually involves the head and face, and is presented commonly as a soft tissue swelling on the rhinofacial area. *Basidiobolus* mainly involves the thigh, buttock or trunk. Both genera cause chronic manifestations, and produce a slowly progressing mass without angioinvasion [4]. The mass usually has minimal signs of inflammation and the patient lacks systemic symptoms [4], as in this study's case, in which *Conidiobolus* infection was suspected. This contradicts cutaneous mucormycosis, which is characterized by an inflammatory response, necrosis, blood vessel invasion and sometimes extension into the deep fascia and muscle. In addition, mucormycosis occurs most often in immunocompromised patients. Both diseases require skin biopsy for definitive diagnosis. Eosinophilia in subcutaneous tissue also can be seen in cutaneous tuberculosis, and parasitic or other fungal infections. The characteristic findings in entomophthoramycosis are broad, sparsely septated hyphae surrounded by eosinophilic granular material [9-11]. Absence of vascular and neural tissue involvement in this case also may aid in diagnosis. Tissue swab culture is negative in most cases. Previous studies reported that the main presentations in 6 cases of adults were nasal swelling or nasal mass [6,7], and one 9-month old infant presented with dacryocystitis [8]. In this case, the patient presented with an eyebrow mass. Previous studies showed a level of eosinophils in the complete blood cell count that ranged from 1-5% [7,8], which was similar to this case showing an eosinophil level of 5%. In this case, only a pathologist's review of the specimens was believed adequate for diagnosing, and an additional biopsy or culture of the lesion was not performed.

In general, the treatment of Entomophthoramycosis consists of surgical removal and antifungal therapy. While amphotericin B is the treatment of choice for mucormycosis, the options for treating entomophthoramycosis include potassium iodide, trimethoprim-sulfamethoxazole, ketoconazole, itraconazole, amphotericin

B, etc [8,12,13]. However, the outcomes of treatment vary. In this case, trimethoprim-sulfamethoxazole and itraconazole were used without an operation, as the mass was small and disappeared after 2-weeks of a 6-week medication course.

Conclusion

Entomophthoramycosis is a fungal infection that can cause subcutaneous masses in immunocompetent persons. Physicians should diagnose entomophthoramycosis based on host characteristics, clinical manifestations (especially soft tissue mass) and histopathologic characteristics. Close monitoring and follow-up after treatment is necessary for patients with entomophthoramycosis.

References

1. **Kontoyiannis DP, Lewis RE.** Agents of mucormycosis and Entomophthoramycosis. In: Mandell GL, Bennett GE, Dolin R, editors. *Mandell, Douglas and Bennett's Principles and Practice of Infectious Diseases*. 7th ed. Philadelphia, Churchill Livingstone; 2010. p. 3257-69.
2. **Ribes JA, Vanover-Sams CL, Baker DJ.** Zygomycetes in human disease. *Clin Microbiol Rev* 2000;13:236-301.
3. **Chandler F KW, Ajwello L.** A colour atlas and textbook of the histopathology of mycotic diseases. London: Wolfe Medical Publishing, 1980.
4. **Prabhu RM, Patel R.** Mucormycosis and entomophthoramycosis: a review of the clinical manifestations, diagnosis and treatment. *Clin Microbiol Infect* 2004;10(Suppl 1):31-47.
5. **Choonhakarn C, Inthraburan K.** Concurrent subcutaneous and visceral basidiobolomycosis in a renal transplant patient. *Clin Exp Dermatol* 2004;29:369-72.
6. **Boonsarngsuk V, Suankratay C, Wilde H.** Presumably entomophthoramycosis in an HIV-infected patient: the first in Thailand. *J Med Assoc Thai* 2001;84:1635-40.
7. **Leopairut J, Larbcharoensub N, Cheewaruangroj W, Sungkanuparph S, Sathapatayavongs B.** Rhinofacial entomophthoramycosis; a case series and review of the literature. *Southeast Asian J Trop Med Public Health* 2010;41:928-35.
8. **Pornpanich K, Uprasertkul M, Luemsamran P, Jantharaworamet B, Vangveeravong S.** Entomophthoramycosis: a rare fungal orbital infection presenting with dacryocystitis. *Orbit* 2011;30:21-3.
9. **Perez JA, Correa A, Fuentes J, Melendez E.** *Conidiobolomycosis*: a case report with histopathologic

- findings. Biomedica 2004;24:350-5.
10. **Nemenqani D, Yaqoob N, Khoja H, Al Saif O, Amra NK, Amr SS.** Gastrointestinal basidiobolomycosis: an unusual fungal infection mimicking colon cancer. Arch Pathol Lab Med 2009;133:1938-42.
 11. **Hussein MR, Musalam AO, Assiry MH, Eid RA, El Motawa AM, Gamel AM.** Histological and ultrastructural features of gastrointestinal basidiobolomycosis. Mycol Res 2007;111(Pt 8):926-30.
 12. **Valle AC, Wanke B, Lazera MS, Monteiro PC, Viegas ML.** Entomophthoromycosis by *Conidiobolus coronatus*. Report of a case successfully treated with the combination of itraconazole and fluconazole. Rev Inst Med Trop Sao Paulo 2001;43:233-6.
 13. **Mathew R, Kumaravel S, Kuruvilla S, et al.** Successful treatment of extensive basidiobolomycosis with oral itraconazole in a child. Int J Dermatol 2005;44: 572-5.

การติดเชื้อราเอนโตมอฟโตรามัยโคซิสที่บริเวณชั้นใต้ผิวหนังในผู้ป่วยเด็กชายอายุ 9 ปี

เพณณินาท์ โอเบอร์ดอร์เฟอร์, พ.บ.,¹ ปิติ เพลินชัยวานิช, พ.บ.,² กฤษณะ คงถาวรสกุล, พ.บ.,¹
เบญจพร ไชยวรรณ, พ.บ.³

¹ภาควิชากุมารเวชศาสตร์ คณะแพทยศาสตร์ มหาวิทยาลัยเชียงใหม่, ²ภาควิชากุมารเวชศาสตร์
โรงพยาบาลเชียงรายประชานุเคราะห์, ³ภาควิชาพยาธิวิทยา คณะแพทยศาสตร์ มหาวิทยาลัยเชียงใหม่

บทคัดย่อ

ผู้ป่วยเด็กชายอายุ 9 ปี มีก้อนใต้ผิวหนังบริเวณเหนือคิ้วด้านขวาเป็นเวลา 2 เดือน ก้อนมีขนาด 2 เซนติเมตรโดยไม่พบว่ามี
การอักเสบที่บริเวณก้อน ผู้ป่วยแข็งแรงดี ไม่มีโรคประจำตัว และไม่มีประวัติได้รับบาดเจ็บมา จากการตรวจชิ้นเนื้อพบ
ลักษณะ eosinophilic granulomas และ broad ribbon like hyphae ซึ่งเป็นลักษณะที่บ่งบอกได้ถึงติดเชื้อราเอนโตมอฟโตรามัยโคซิส โดยผู้ป่วยได้รับการรักษาด้วยยา trimethoprim-sulfamethoxazole และ itraconazole เป็นระยะเวลา 6 สัปดาห์
ภายหลังการรักษาพบว่าก้อนใต้ผิวหนังที่บริเวณเหนือคิ้วหายไป **เชียงใหม่เวชสาร 2555;51(4):125-129.**

คำสำคัญ: เอนโตมอฟโตรามัยโคซิส การติดเชื้อรา

