

# The literature review of Ollier disease

**Witchuree Wejjakul, M.D., Dumnoensun Pruksakorn, M.D.,  
Yuddhasert Sirirungruangsarn, M.D., Sirichai Luevitoonvechkij, M.D.,  
Songsak Khunsree, M.D., Tanawat Vaseenon, M.D.**

Department of Orthopedics, Faculty of Medicine, Chiang Mai University

---

Ollier disease is a rare disease with an incidence 1:100,000. It is a multiple benign hyaline-cartilaginous-forming tumor at metaphysis or extended to diaphysis of bone. This paper reviews the Ollier disease and its general, pathogenesis, clinical presentations, investigation findings and the treatment which still has no consensus. **Chiang Mai Medical Journal 2013;52(3-4):73-79.**

---

**Keywords:** Ollier disease, enchondromatosis, multiple enchondromatosis, dyschondroplasia

## General of disease

Enchondroma is a common, benign, hyaline-cartilage-forming tumor in the medulla of the bone, occurs at metaphysis or extended to diaphysis, and usually a single lesion. When there are multiple enchondromas, the term enchondromatosis is applied. There are 7 subtypes of enchondromatosis; the most common subtypes are Ollier disease and Maffucci syndrome which are distinguished by the presentation of hemangioma. When enchondromatosis presents with hemangioma, it is named Maffucci syndrome, without hemangioma is named Ollier disease.

Ollier disease is also known as dyschondroplasia, multiple cartilaginous enchondromatosis or enchondromatosis Spranger type I. It is a rare non-hereditary congenital disease. The incidence is 1:100,000 but can be higher because of the under-detection of the mild phenotypes without skeletal deformities [1]. There is no difference between male and female.

## Pathogenesis

The pathogenesis of Ollier disease is unknown, but the irregular distribution of the lesions strongly suggests that it occurs from early post-zygotic genetic events [2,3] and is a mosaic condition because of its non-hereditary and unilateral predominant features [3]. The hypothesis of the formation of enchondromatosis is the abnormalities in signaling pathways controlling the proliferation and differentiation of chondrocytes, which causes the failure in the enchondral bone ossification process. Hopyan *et al* identified a mutation of parathyroid hormone-related protein (PTHrP) which bound to PTHR1 receptor in enchondromatosis [4]. When the heterozygous mutation of PTHR1; also called R150C, took place, enchondromatosis developed [3,5]. However there are some reports demonstrated that the mutant PTHR1 was found only 10 percent in patients with Ollier disease [2,3], and the decreasing function of the receptor is approximated 70 percent.

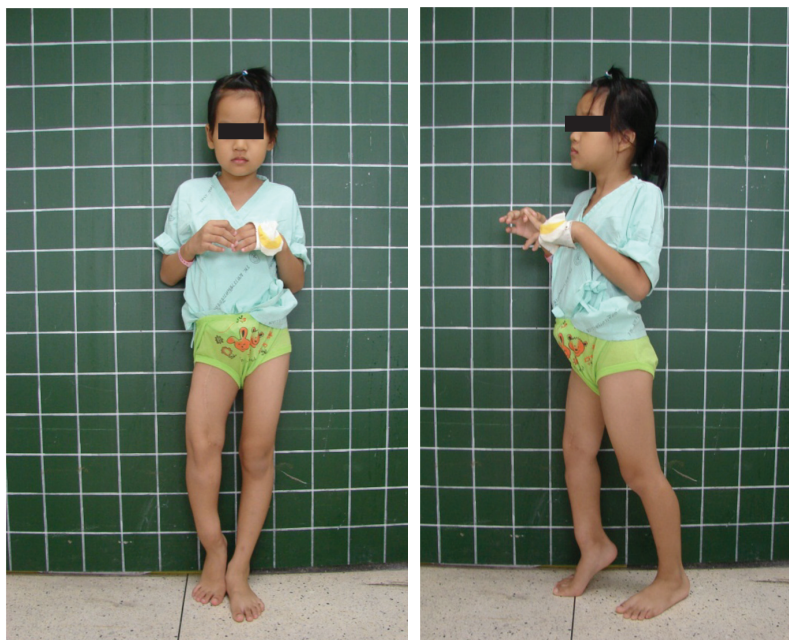These suggest that mutant PTHR1 may contribute to but is not the actual cause of the disease [3]. Moreover than mutant PTHR1, there are also other mutant genes found in enchondromatosis, which are FAM86D, PRKG1, ANKS1B, NIPBL and POUF51, but most of these genes have no important role in cartilage formation, [3] so there should be the further studies to find out what is the actual pathogenesis of the disease that will help us understanding more about Ollier disease.

### Clinical presentation

Ollier disease can present with clinical features of mass and limb-length discrepancy. The mass or swelling occur closed proximity to growth plate of long tubular bone (femur, tibia, humerus, fibula), small bone of hands or feet (carpal, metacarpal, phalanges, tarsal, metatarsal bones), and flat bone (pelvis) [2,6]. It is rarely involved vertebrae and skull [1]. The distribution of the lesions is usually asymmetric that localized unilateral, if bilateral, there will be one dominant side [6]. Three case reports of Ollier disease pre-

sented that the mass usually occurred in hand and foot [7-9]. It is less frequently seen in the foot than in the hand. Limb-length discrepancy presents as limb shortening causing gait abnormalities, and is usually seen with angular deformity such as varus, valgus, or distortion in longitudinal growth of bone [6, 10-12], and can cause the limiting of articular movement and pathologic fracture.

The importance of Ollier disease is that there can be malignant transformation, which frequently develop into chondrosarcoma; a malignant hyaline-cartilage-forming tumor with no marker can indicate, about 25-30 percent of Ollier patients [1,9,10,13], and some develop into osteosarcoma [10,14]. There are non-skeletal malignant lesions those are gliomas [2,13] and juvenile granulosa cell tumors [2]. Patients are likely to die from non-skeletal tumor, so the examination of the other organs that have a predilection to malignant degeneration is very important for orthopaedic surgeons to get early diagnosis and give them the proper management.



**Figure 1.** A 9-year-old girl presented with gait abnormality since she was 9 months. The physical examination showed right genu varum with limb-length discrepancy of right femur and tibia.

## Diagnosis

Clinical presentation and radiological findings are the keys to diagnosed Ollier disease. Histopathology helps when malignancy is suspected. Only the clinical features are not enough for the diagnosis because there are many diseases that can present with these features, the correlation between clinical presentation and radiological findings is needed for definitive diagnosis. The radiographs show multiple, radiolucent, homogenous, oval or elongated-shape lesions, usually well-defined and has an axis runs parallel to the long bone axis which distinguish enchondromatosis from malignant tumor. Malignant lesion presents with poor demarcation. If there is a cortical destruction or soft tissue extension, the risk of chondrosarcoma significantly increases about 2.3 percent [2]. When malignancy is suspected, the histopathological investigation is used for grading because different grade requires different management [1]. Magnetic resonance imaging (MRI) demonstrates lobulated lesions with intermediate signal intensity on T1-weighted images and predominantly high signal intensity on T2-weighted sequences [6], however, routine use of MRI is not recommended because plain radiographs provide adequate information.

## Treatment

There is no medical treatment for Ollier disease except to relieve symptoms such as pain. The surgical treatment is required when there is any complication; pathological fracture, malignant transformation, growth defect, and cosmesis.

In the cases with enchondromal mass, the curettage with bone grafting is used for completely eradicate the mass. In fact, it is impossible to completely eradicate the mass because the affected bone is weak, difficult for internal stabilization and required large amount of bone graft to correct the extensive discrepancy and may be multiple areas [4,11]. Due to these problems, there are some studies recommended other material which can be used instead of autologous cancellous bone graft. The alpha-tricalcium phosphate

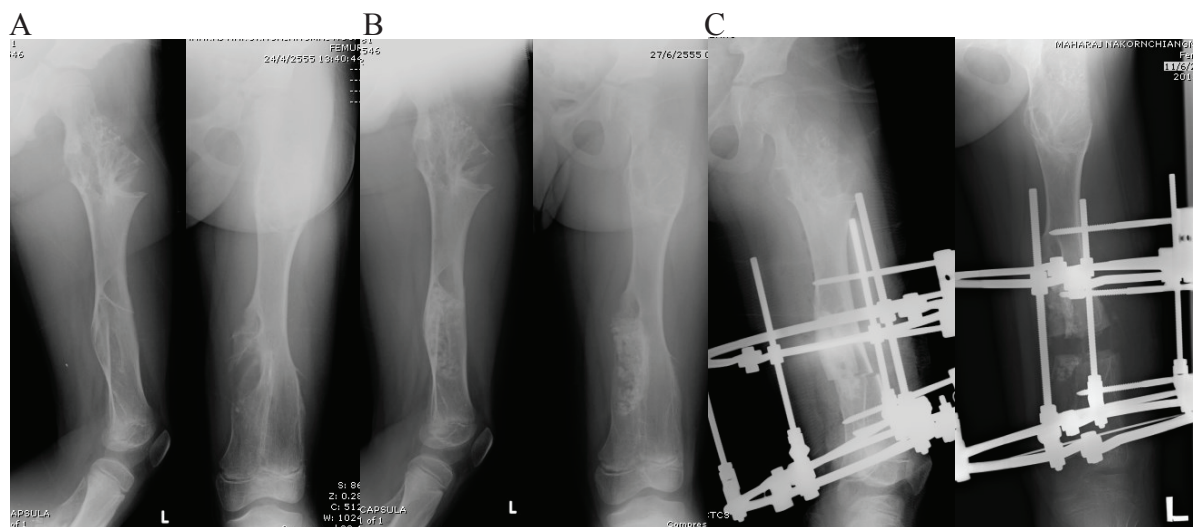
cement is used to fill the cavity with good results of providing an excellent stabilization, allowing early mobilization and having a little resorption. After tumor curettage, casting was employed for 4 weeks to prevent postoperative pathological fractures. There is possible concern that if there is a relapse of tumor in the future, the remaining material may make it difficult to reoperate [15]. Calcium hydroxyapatite (CHA) was used in 2 studies in 1990 and 2000 [16,17]. Its advantages were safe and convenient in facilitating the regeneration of bone defects from surgical excision of benign tumors. It is a non-toxic substance that provokes few reaction from the tissue. The follow-up after the treatment shows no local recurrent tumor, no adverse effect from the implants such as excessive postoperative drainage, erythema or other wound problems. The radiography demonstrated new bone formation in and around CHA which increasing during postoperative period that shows well-incorporated of CHA graft into host bone. The postoperative complications are pain and fractures which accidental occurred in one case and another because the patient did not follow the instructions on bearing weight, but both diminished with time. In Ollier patients who have multiple masses that usually interfere the function of involved organ and sometimes caused pain, the curettage is necessary for getting rid of the masses and then filling the cavity with artificial bone graft for good stabilization of the affected bone. There are the studies showed that filling the cavity with either alpha-tricalcium phosphate or calcium hydroxyapatite (CHA), provided good results with little complications that can be corrected or spontaneously resolved.

Ollier disease with limb-length discrepancy, the effective treatment is distraction osteogenesis with the use of Ilizarov instrument. The reason for using external fixator rather than internal fixator is that it is difficult to use the internal fixator in the patients' fragile, pathological bone. The most important treatment goals are to achieve good mechanical realigned and equal limb length for normal gait and relieving pain from pathological fracture. There are many studies

regarding the correction of limb-length discrepancy in both benign tumors and focusing in Ollier disease alone [4,11-13,18-24]. Most of cases are fully corrected the limb-length discrepancies and angular deformities by using asymmetric distraction at least one operation, but in most cases, the second operation was necessary. The conversion of enchondromal mass into normal new bone regeneration can be seen on radiographs at the follow-up time. Some studies reported that there is the conversion of the abnormal cartilage to histologically mature bone [12,18]. However, there are some complications such as pain during distraction which can be managed by oral analgesic and temporary stopping distraction or slowing distraction rate. Pin-track infection is also a common complication, but none of the patients got severe infection which causes morbidity and mortality. All can be cured by antibiotics either oral or intravenous form with or without surgical drainage and followed by the good pin care. Neurapraxia can be presented soon after surgery and spontaneously resolved. Other complications that can be found

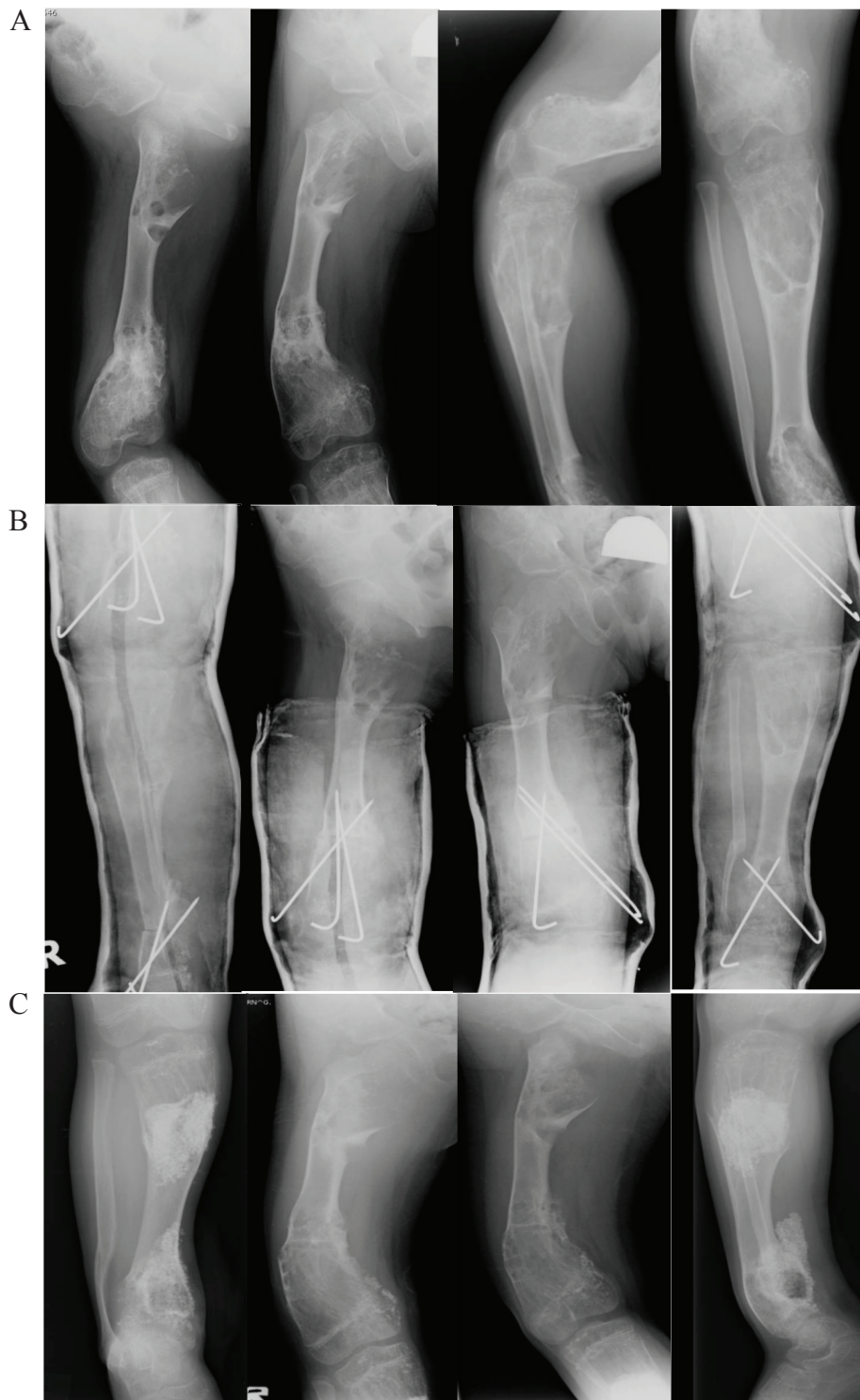are flexion contractures, joint stiffness [21], incomplete fracture [4], and nonunion [19]. The lengthening rate is about 0.5-1.5 mm per day [4,11,12,23]. The external fixation indexes are 26[4], 39[11], 49.2[19] days per cm respectively. The recommendation for the treatment of limb-length discrepancy in Ollier patient should be the surgical procedure; asymmetric distraction osteogenesis with Ilizarov instrument, and better be done as early as the diagnosis is done. Most cases need more than one operation. Many studies showed that this surgical procedure gave an excellent outcome with correctable complications.

The postoperative rehabilitation play an important role and need the patients' cooperation. There is a study showed that after one month of rehabilitation treatment; taking analgesic drugs, underwent physical therapy such as ultrasound, cryotherapy, CO<sub>2</sub> laser, with stretching, active mobilization, the pain is relieved with a significant decreased dose of analgesic drugs and improvement of articular function, muscular strength and resistance, and better Activity of Daily Living [24].



**Figure 2.** An 8-year-old boy presented with left thigh swelling with hip and thigh pain on movement. **A**, Pre-operative radiographs showed multiple, radiolucent, well-defined, elongated shape lesions run parallel to bone axis at metaphysis extended to diaphysis of left distal femur. **B**, After the operation (curettage with hydroxyapatite bone graft), the lesions were filled with HA with little new bone formation around. **C**, Post-operative corrective osteotomy with Ilizarov bone lengthening. (The patient is continuously retaining the Ilizarov)





**Figure 3.** A 9-year-old girl in **A**, Pre-operative radiograph showed multiple radiolucent, oval-shape lesions at metaphysis extended to diaphysis of right proximal and distal femur and tibia. **B**, Post-operative Corrective Osteotomy right distal femur and tibia and fibula with nails and long leg cast. **C**, At the 3-year follow-up time.

## Acknowledgement

Thanks to Dr.Dumnoensun Pruksakorn, Dr.Yuddhasert Sirirungruangsarn, Dr.Sirichai Luevitoonvechkij, Dr.Songsak Khunsree and Dr. Tanawat Vaseenon for all helps and advices.

Thanks to the two patients for the information, pictures and radiographs.

Conflict of Interest none

## References

1. **Pansuriya TC, Kroon HM, Bovée JVMG.** Review Article Enchondromatosis: insights on the different subtypes. *Int J Clin Exp Pathol* 2010;3:557-69.
2. **Verdegaal SHM, Bovée JVMG, Pansuriya TC, et al.** Incidence, Predictive Factors, and Prognosis of Chondrosarcoma in Patients with Ollier Disease and Maffucci Syndrome: An International Multicenter Study of 161 Patients. *The Oncologist* 2011;16:1771-9.
3. **Pansuriya TC, Oosting J, Krenács T, et al.** Genome-wide analysis of Ollier disease: Is it all in the genes?. *Orphanet Journal of Rare Diseases* 2011;6:1-11.
4. **Kolodziej L, Kolban M, Zacha S, Chmielnicki M.** The use of the Ilizarov technique in the treatment of upper limb deformity in patients with Ollier's disease. *J Pediatr Orthop* 2005;25:2002-5.
5. **Couvineau A, Wouters V, Bertrand G, et al.** PTHR1 mutations associated with Ollier disease result in receptor loss of function. *Human Molecular Genetics* 2008;17:2766-75.
6. **Silve C, Jüppner H.** Review: Ollier disease. *Orphanet Journal of Rare Diseases* 2006;1:1-6.
7. **Casal D, Mavioso C, Mendes MM, Mouzinho MM.** Hand Involvement in Ollier Disease and Maffucci Syndrome: A Case Series. *ACTA REUMATOL PORT.* 2010;35:375-8.
8. **Khoo RN, Peh, WCG, Guglielmi G.** Clinics in diagnostic imaging (124). *Singapore Med J* 2008;49:841-6.
9. **Choh SA, Choh NA.** Multiple enchondromatosis (Ollier disease). *Ann Saudi Med* 2009;29:65-7.
10. **Schwartz HS, Zimmerman NB, Simon MA, Wroble RR, Millar EA, Bonfigli M.** The malignant potential of enchondromatosis. *J Bone Joint Surg Am* 1987;69:782-92.
11. **Watanabe K, Tsuchiya H, Sakurakichi K, Yamashiro T, Matsubara H, Tomita K.** Treatment of lower limb deformities and limb-length discrepancies with the external fixator in Ollier's disease. *J Orthop Sci* 2007;12:471-5.
12. **Märtson A, Haviko T, Kirjanen K.** Extensive limb lengthening in Ollier's disease: 25-year follow-up. *Medicina (Kaunas)* 2005;41:861-6.
13. **Hori K, Matsumine A, Niimi R, Maeda M, Uchida K, Nakamura T, Sudo A.** Diffuse gliomas in and adolescent with multiple enchondromatosis (Ollier's disease). *Oncology Letters* 2010;1:595-7.
14. **Braddock GTF, Hadlow VD.** Osteosarcoma in Enchondromatosis (Ollier's Disease). *J Bone Joint Surg [Br]* 1966;48-B:145-9.
15. **Sasaki D, Hatori M, Abe Y, Kokubun S.** Ollier's Disease Treated with Grafting Using Alpha-tricalcium Phosphate Cement: A Case Report. *Upsala J Med Sci* 2006;111:249-56.
16. **Uchida A, Araki N, Shinto Y, Yoshikawa H, Kuri-saki E, Ono K.** The Use of Calcium Hydroxyapatite Ceramic in Bone Tumour Surgery. *J Bone Joint Surg [Br]* 1990;72-B:298-302.
17. **Yamamoto T, Onga T, Marui T, Mizuno T.** Use of hydroxyapatite to fill cavities after excision of benign bone tumours. *J Bone Joint Surg [Br]* 2000;82-B:1117-20.
18. **Tsuchiya H, Morsy AF, Matsubara H, Watanabe K, Abdel-Wanis ME, Tomita K.** Treatment of benign bone tumours using external fixation. *J Bone Joint Surg [Br]* 2007;89-B:1077-83.
19. **Raimondo RA, Skaggs DL, Rosenwasser MP, Dick HM.** Lengthening of Pediatric Forearm Deformities Using the Ilizarov Technique: Functional and Cosmetic Results. *J Hand Surg* 1999;24A:331-8.
20. **Haddad FS, Harper GD, Hill RA.** Intraoperative Arthrography and the Ilizarov Technique: Role in the correction of paediatric deformity and leg lengthening. *J Bone Joint Surg [Br]* 1997;79-B:731-3.
21. **Pandey R, White SH, Kenwright J.** Callus distraction in Ollier's disease. *Acta Orthop Scand* 1995;66:479-480.
22. **Baumgart R, Bürklein D, Hinterwimmer S, Thaller P, Mutschler W.** Case report: the management of leg-length discrepancy in Ollier's disease with a fully implantable lengthening nail. *J Bone Joint Surg [Br]* 2005;87-B:1000-4.
23. **Gabos PG, Bowen JR.** Epiphyseal-Metaphyseal Enchondromatosis: A New Clinical Entity. *J Bone Joint Surg [Br]* 1998;80-A:1000-4.
24. **Formis A, Allegri S, Posteraro L.** Rehabilitation experience in a case of Ollier's disease. *Acta Bio Medica Ateneo Parmense* 2003;74:151-6.

## บทความเชิงวิเคราะห์โรค Ollier: อาการทางคลินิก การวินิจฉัย และการรักษา

วิชชุรีย์ เวชชากุล, พ.บ., ดำเนินสันต์ พฤกษากร, พ.บ., ยุทธเสริฐ ศิริรุ่งเรืองสาร, พ.บ.,  
ศิริชัย ลือวิฑูรย์เวชกิจ, พ.บ., ทรงศักดิ์ ขุนศรี, พ.บ., ธนวัฒน์ วัฒินนท์, พ.บ.  
ภาควิชาออร์โธปิดิกส์ คณะแพทยศาสตร์ มหาวิทยาลัยเชียงใหม่

---

Ollier disease คือเนื้องอกกระดูกอ่อนชนิดไม่ร้ายแรงที่เกิดขึ้นหลายตำแหน่ง โดยมักพบบริเวณ metaphysis ของกระดูกหรือ  
อาจลุกลามเข้าไปถึงบริเวณ diaphysis ได้ โรคนี้พบได้ไม่บ่อยนัก โดยมีอุบัติการณ์ 1:100,000 บทความนี้ได้ทบทวนงานวิจัย  
เกี่ยวกับ Ollier disease และได้สรุปภาพรวมของโรค พยาธิกำเนิด ลักษณะอาการทางคลินิก สิ่งตรวจพบจากการส่งตรวจ  
เพิ่มเติม และวิธีการรักษาซึ่งยังไม่มีข้อสรุปที่แน่ชัด **เชียงใหม่เวชสาร 2556;52(3-4):73-79.**

---

**คำสำคัญ:** เนื้องอกกระดูก โรคเนื้องอกกระดูก เนื้องอกกระดูกในเด็ก

